

MUSCULOSKELETAL¹

I. INTRODUCTION

A. OUTLINE OF COMMON CLINICAL CONDITIONS:

- Neck: 1) Cervical Pain, Radiculopathy, and Neck Surgery
- Back: 2) Lumbar Pain, Radiculopathy, and Spine Surgery
- 3) Spinal Deformity (Scoliosis)
- 4) Spondylolisthesis
- 5) Miscellaneous Lumbar Spine Conditions
- Lower Extremity: 6) Meniscal Injuries
- 7) Loose Body in the Knee
- 8) Patellofemoral Problems
- 9) Anterior Cruciate Ligament Instability
- 10) Collateral Ligament Instability
- 11) Shin Splints [Medial Tibial Stress Syndrome (MTSS)]
- 12) Ankle Instability
- 13) Iliotibial Band Syndrome
- Upper Extremity: 14) Acromioclavicular (AC) Joint Separation
- 15) Anterior Shoulder Subluxation and Dislocation
- 16) Rotator Cuff Disease
- 17) Finger Amputations/Arthrosis
- 18) Carpal Tunnel Syndrome
- Miscellaneous: 19) Retained Orthopedic Hardware

¹ **Authors:** Douglas Chang, M.D., Ph.D. and Catherine Robertson, M.D. (MED-TOX and UC San Diego) with assistance from R. Leonard Goldberg, M.D. **Specialist Review Panel:** Cindy Chang, M.D.; Michael Fredericson, M.D.; Stanley Herring, M.D.; Kristofer Jones, M.D.; Margot Putukian, M.D.; and Alexander Vaccaro, M.D.

B. IMPLICATIONS FOR JOB PERFORMANCE:

Abnormalities in the musculoskeletal system may limit an officer's ability to perform numerous essential functions, including:

- **Running** in pursuit of suspects for distances up to 500 yards. Speed is important in up to 90% of incidences.
- **Balancing and walking** several yards at 6-10 feet above ground on top of walls or other surfaces which are most frequently only 6" wide.
- **Climbing** 6' fences, 2-5 flights of stairs, 20' ladders, and 36' embankments where speed is required 33% of the time.
- **Jumping/Hurdling/Vaulting** across 3-5' ditches, down from 6' walls, and over 3' shrubs. Speed is required 90% of the time. One third of these events occur from a stationary position.
- **Moving incapacitated persons:** lifting and carrying someone without assistance for distances averaging 40'. Speed is critical in 40% of instances.
- **Pushing vehicles, dragging and pulling objects** averaging 60 lbs., without assistance, where speed is required 50% of the time.
- **Crawling/crouching/squatting**
- **Subduing combative subjects**
- **Firearm and weapon handling** including the use of batons, resisting take-away attempts by suspects, and maintaining stability of the arm and wrist despite recoil forces of up to 48 lbs. (shotguns).

Critical incidents requiring physical exertion occur an average of 18 times/year. In two-thirds of these incidents, failure to perform could result in injury to the officer or to the public (Berner et al., 1985).

II) MEDICAL EXAMINATION AND EVALUATION GUIDELINES

A. GENERAL SCREENING RECOMMENDATIONS:

1) History: The following information should be obtained for each incidence of musculoskeletal injury:

- ***How did the injury occur, and did it result in a personal injury or workers' compensation award?***

Assess the contribution of litigation to protracted treatment periods or disability.

- ***Date of injury, first symptom, first evaluation and treatment, most recent symptom, most recent treatment and evaluation.***

When injuries result in litigation, these dates are often very different and can be important in determining the true severity of the injury. For example, it is not uncommon for whiplash victims to have symptoms which begin 1-2 days after the accident as muscle spasm and inflammation develop. Symptoms that develop immediately may indicate a more severe injury. Symptoms that develop a week or later or longer may have been augmented after coaching from a lawyer's office. Alternatively, as one set of symptoms resolve, others may become more apparent.

The date of first treatment may also provide important information. The dates of the most recent symptom, evaluation and treatments should be asked in separate questions. The candidate should explain any discrepancy greater than 2-3 weeks. In personal injury cases, it is not uncommon for candidates to report that treatment lasted for months after being asymptomatic. Medical record review will reveal the candidate's reported symptoms during the entire length of treatment. If the candidate's subjective recall of historical events remains at odds with the medical record, the written medical record should be seen as the more reliable.

The agency should be informed if the candidate admits lying to a previous health care provider in an attempt to defraud an insurance company or former employer. This information is relevant to the candidate's background investigation.

The candidate should be asked if there have been any evaluations subsequent to the termination of treatment. These evaluations may have been conducted as either part of a permanent disability determination or a pre-placement evaluation by another agency.

- The candidate should be thoroughly questioned regarding the ***extent of the disability***, including such questions as:
 - *What was the impact of the injury or pain occurrence?*
 - *Did limitations in sitting, standing, lifting, or walking occur?*
 - *How many days of work were lost?*
 - *How long were work restrictions necessary?*
 - *Did the candidate return to the same work duties?*
 - *Did the candidate work despite the presence of pain?*
 - *Was a permanent disability awarded?*
 - *What was the impact of the injury on participation in sports?*
 - *Are there any current symptoms or residual impairment of functional ability?*
- The candidate should also be asked about any **problems since recovery**.

2) Examination:

The most common anatomical locations for acute injuries, as evidenced by FBI new agent trainees, are knees (10%), thighs (8%), shoulders (7.5%), fingers (7.5%), low back (6%), face (5.5%), head (5%), and ankles (5%). For trainees requiring follow-up medical attention, the most common locations involved ankle, shoulder, knees, thigh and head (Knapik et al., 2011).

For candidates with a negative history, the examination should consist of the following components:

- **Inspection** of all extremities for scars, obvious atrophy or deformity.
 - **Upper Extremity:** Joint mobility (range of motion), joint stability (apprehension test for shoulder instability), and neurological examination for reflexes, strength and sensation.
 - **Back:** Heel/toe walk, range-of-motion in forward flexion and backwards extension, inspection, and palpation, and neurological examination in the lower extremities. The straight leg raise (SLR) test has poor specificity (Deville et al., 2000) and variable sensitivity (van der Windt et al., 2010). The SLR has limited diagnostic ability to identify lumbar disc herniation, and little predictive value for future lower back pain or disability (Waddell & Burton, 2001).
 - **Knees/Ankles/Hips:** Duck walk and squat (note any difficulty or asymmetry), inspection (note any scars, atrophy of the vastus medialis obliquus muscle, or effusion), test for anterior cruciate, posterior cruciate, and collateral ligamentous laxity at 30 degrees of flexion, and screen for patellar apprehension. For candidates with a history of knee surgery, the bilateral thigh circumference should be measured at 10 cm. proximal to the superior pole of the patella with active straight leg raising (note differences >1/2"). Candidates with a history of knee surgery should perform a one-legged hop bilaterally (normal symmetry is +/-15%). More detail regarding these tests is provided below and in Henning et al. (1986).
 - **Neurological examination** for reflexes, strength and sensation in the upper and lower extremities.
- 3) Routine Testing: For candidates with a negative history – including the results of physical ability testing and x-ray examination, if available – no routine testing of the musculoskeletal system is necessary.

B. EVALUATION OF COMMON CLINICAL CONDITIONS:

1) Cervical Pain, Radiculopathy, and Neck Surgery

a. General Considerations:

Pervasiveness of Cervical Pain:

- 1.5% of all visits to a U.S. physician in 2004 were for neck pain (American Academy of Orthopaedic Surgeons, 2008).
- Neck pain is about as common as back pain, with a lifetime prevalence of 70% (Nachemson et al., 2000).
- Each year about 5% of workers will develop frequent, persistent neck disorders (Cote et al. 2008).
- Among military pilots, wearing helmets has been shown to be a risk factor for increased neck pain (Ang et al., 2009). Neck pain can affect mission safety by compromising the ability of helmeted individuals to turn their heads for proper surveillance behind them.
- Certain soft-tissue and bony abnormalities of the cervical spine can result in sudden pain or even neurological compromise of the extremities if the neck is jarred or subjected to extreme ranges of motion. If this occurs during a critical incident, the safety of the officer and the public could be jeopardized

The identification of candidates who are at significantly increased risk is difficult due to the following:

- Risk factors for neck pain involve a complex relationship of individual, work-related and cultural variables (Cote et al., 2008; Hoy et al., 2010) such as age, gender, posture, workstation design, social support network, an urban versus rural environment, and region/country.
- The course and prognosis of neck pain in workers is affected by epidemiologic and psychosocial factors (Carroll et al., 2008). A poorer prognosis is seen with workers who have little influence over their own work situation, don't exercise, are involved with blue-collar work, or have a history of prior neck pain involving use of sick leave.
- Among asymptomatic persons, cervical spine x-rays will show evidence of degenerative changes in 35% of 40-45 year olds, and 75% of 50-55 year olds. On 10 year follow-up, only 15% of this cohort developed neck pain, an incidence that is actually less than that seen in other studies (Gore, 2001).
- A cervical spine MRI demonstrates a herniated disc in 10% of asymptomatic adults younger than 40 years old (Boden, McCowin et al., 1990). The MRI may show posterior disc protrusion with actual spinal cord compression in 8% of asymptomatic adults (Matsumoto et al., 1998).

In summary, neck complaints are common, their severity is often influenced by non-physical factors, and poor specificity limits the usefulness of radiographic studies (Bogduk, 1999; Ferrari & Russell, 2003). Therefore, the assessment of cervical conditions must be based on criteria with the highest specificity possible. Although not an exhaustive list, these criteria include:

- **Current limitation of activity:** Heavy lifting or other activities significantly aggravate neck pain (Wiesel, 1989). Working conditions that aggravate neck pain include heavy physical work demands, head posture while working at a computer, regular bending and twisting, and working with the hands above the shoulders (Cote et al., 2008).
- **Current EMG-NCS evidence of radiculopathy:** A needle EMG study provides the most specific evidence that cervical pathology has clinical significance (e.g., loss of grip strength). An EMG is best used to evaluate radicular or peripheral nerve symptoms; it is generally not helpful for assessing axial (non-radiating) neck pain. EMG findings of abnormal spontaneous activity (i.e. positive sharp waves or fibrillation potentials) indicate muscle denervation of a sub-acute time-frame (Chang & Date, 2009). In these cases, it is reasonable to assume that cervical stress (for example, due to sudden forced flexion/extension) during a critical incident could worsen the radiculopathy, resulting in acute impairment.

Electrophysiologic exams should also include nerve conduction studies (NCS), in addition to needle EMG. NCS is useful to rule-in a peripheral neuropathy (i.e. carpal tunnel syndrome or diabetic polyneuropathy) that could affect hand function. However, due to its poor sensitivity, an EMG study should not be used to exclude a radiculopathy (Chang & Date, 2009).

- **Symptomatic candidates with a prior history of cervical spine surgery:** Flexion/extension radiographs can be helpful to detect infection, surgical implant failure, pseudarthrosis, or instability (Rihn et al., 2012). Symptomatic candidates with a prior history of cervical spine surgery should have flexion/extension radiographs and undergo an evaluation by a board-certified spine specialist (i.e., physiatrist, neurologist or surgeon) to obtain clearance.
- **Asymptomatic candidates who have a history of cervical laminectomy without fusion:** Some individuals with central cervical spinal stenosis (congenital and acquired), myelopathy, multi-level radiculopathy, infection, neoplasm or posterior longitudinal ligament ossification may have been treated with a cervical laminectomy without fusion (Klineberg, 2010). Such individuals are at risk for postoperative nerve root deficits, deformity, cervical instability and late deterioration (McAllister et al., 2012; Epstein, 2003). Those who are considered candidates for a cervical laminectomy without fusion are typically elderly individuals with multiple comorbidities and with adequate spinal alignment.

- **History of transient quadriplegia-paresis:** These conditions arise from transient compressive deformation of the spinal cord and are totally reversible. They may occur in individuals with a congenitally narrowed spinal canal. Certain specific history and findings could lead to recommendations for restricted activity (Vaccaro et al., 2002; Torg, 1995; Concannon et al., 2012). An individual with a documented history of transient quadriplegia-paresis would fall into Group II below.

Transient quadriplegia is a rare transient neurologic injury, occurring in 7.3 per 100,000 football players. It occurs in the absence of a structural abnormality (apart from congenitally narrow spinal canal) and typically lasts for ~15 minutes, although it can endure up to 48 hours. An athlete with a single episode of transient quadriplegia-paresis and a normal spinal cord and spine usually recovers well, although longer-term outcome data is sparse. In the immediate term, there is no absolute contraindication to return to full contact activities for individuals properly evaluated and cleared by a spine specialist. Players with this condition who have benign anatomic findings are thought to be at no greater risk for a permanent catastrophic neurologic injury (Torg et al., 1996). However the true risk has yet to be established due to the small incidence of transient quadriplegia-paresis and spinal cord injury in athletes (Concannon et al., 2012).

Players with a documented episode of transient quadriplegia should not return to collision sports if they have ligamentous instability, disc disease with cord compression, significant spine degenerative changes, MRI evidence of spinal cord defect, more than one recurrence, or neurological findings lasting more than 36 hours. There is a 56% rate of recurrence for those who return to football (Torg et al., 1997).

- **History of temporary traumatic “stingers” or “burners”** arise from unilateral injury to the brachial plexus (usually the upper trunk) or cervical nerve roots (usually C5 or C6). Although common in contact sports, their true incidence is unknown due to under-reporting by athletes. As a result, the long term outcome of this condition is unknown. The reported injuries are usually brief and self-limited, but recovery can take weeks to months in severe cases. Bilateral symptoms, such as “burning hands syndrome,” represent a different condition, suggestive of a spinal cord injury until proven otherwise. A first stinger with rapid (i.e., minutes) and complete resolution of symptoms is not a contraindication to a full return to sports. All other presentations require further diagnostic evaluation (Concannon et al., 2012), and would fall into Group II below.
- **Cervical instability:** An individual with a documented history of cervical instability would fall into Group II below.

Cervical instability is indicated when horizontal displacement exceeds that found in the normal cervical spine (3.5 mm: Figure VIII-1), or angular differences exceed 11 degrees (Figure VIII-2), even when measured at

extremes of flexion and extension (White et al., 1975). Instability is also suggested with excessive motion (i.e. >2 mm difference) between the spinous processes seen on flexion and extension radiographs (Rihn et al., 2012).

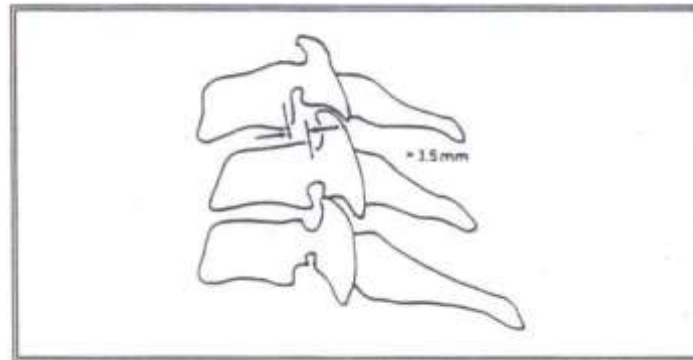


Figure VIII-1. Horizontal Displacement Greater than 3.5 mm of One Vertebra in Relation to an Adjacent Vertebra

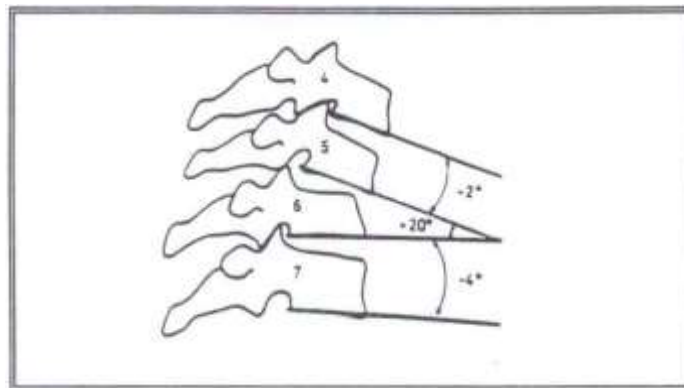


Figure VIII-2. Rotational Difference between Adjacent Vertebra

(Figures VIII-1 and VIII-2 reproduced with permission from White A.A. et al., 1975. Biomechanical analysis of clinical stability in the cervical spine. Clin Orthop Rel Res. 109:85-96.)

Instability commonly arises from trauma, resulting in cervical fractures or severe disruption of the posterior ligaments. In an acute injury, flexion/extension radiographs may appear normal due to muscle spasm, pain and guarding. Therefore, emergency room trauma protocols include CT and/or MRI evaluation of the cervical spine with potential for immediate spine surgery consultation, since instability creates a substantial risk of catastrophic neurological compromise.

Due to advances in trauma protocols, cervical instability is now rarely seen in an ambulatory office setting. Flexion/extension radiographs provide little additional information for asymptomatic individuals with a prior history of cervical spine fusion (Grimm et al., 2013), or for trauma patients who have already been evaluated by a CT or MRI (Sierink et al., 2013). However,

symptomatic candidates with significant prior history (i.e., cervical spine surgery, rheumatoid arthritis, trauma not evaluated by CT or MRI) should be evaluated by a spine specialist.

b. Recommended Evaluation Protocol:

Medical history must establish the extent to which the candidate has experienced periods of:

- **Isolated neck pain with no apparent functional significance.** Candidates deny any limitation or restriction in work, daily activities, or sports.
- **Radicular symptoms** are radiating symptoms (neuropathic pain, disturbed sensation and/or motor weakness) along a characteristic dermatomal distribution in the upper extremity. Such symptoms are suggestive but not diagnostic of neural compromise.
- **Myelopathic symptoms.** Spinal cord compression may occur acutely or progress slowly, causing a myriad of symptoms. There can be neck pain and stiffness, tingling/numbness in the extremities, intermittent shooting pain in the arms and legs, weakness lifting objects, dropping things, coordination problems/clumsiness with fine motor skills (e.g. handwriting or buttoning clothes), heavy feelings in the legs, inability to walk at a brisk pace, loss of balance, or a wide-based gait.
- **Limitation of activities** may be secondary to impairment, avoidance, or restriction. Assessment of activity levels in the post-morbid state can be biased by pre-morbid activity levels. For example, an active candidate might report a history of activity limitation, whereas a sedentary candidate might not.

Medical record review to confirm the candidate's history is especially important when litigation was involved. The results of any previous diagnostic test, such as an MRI, CT, or EMG-NCS, should be obtained.

A thorough neck examination should be performed, including range of motion, palpation, and neurological screening for evidence of radiculopathy or myelopathy. Range of motion should be performed with the neck in neutral position and full flexion and extension, and side glance to the left and to the right.

GROUP I: No history of fracture/dislocation at any time, and no limitations, or no radicular symptoms in the last three years

No restrictions or further evaluation (including radiographs) can be justified unless the physical exam is abnormal.

Candidates with rheumatoid arthritis should get a C spine x-ray 4 views (AP-AP Odontoid view-lateral flexion/extension). Repeat x-rays performed every 3 years are suggested due to the high incidence of significant cervical spine involvement

in this condition (Shen et al., 2004; Nguyen et al., 2004). However, the need for repeat x-rays could be re-evaluated in the absence of ongoing cervical pain or neurological signs/symptoms.

GROUP II: Not meeting criteria for GROUP I

Obtain C Spine AP/Lateral radiographs. Plain films have been used historically to detect obvious fractures, disk space narrowing, osteophyte formation, instability, tumor, foreign bodies, alignment, or implant positioning. They are advantageous from a cost and availability standpoint.

Candidates with neck pain and a history of C spine surgery should get a C spine x-ray 3 views (AP-Lateral flexion/extension).

Candidates with neck pain and radicular pain: X-rays may offer a false sense of reassurance, given their poor sensitivity and specificity for evaluating cervical radiculopathy (Onks & Billy, 2013). In one study, the positive predictive value of conventional radiographs for myelographic nerve root deformity was only 56%, while the negative predictive value was 87% (Mink et al., 2003). The North American Spine Society guidelines advise C-spine MRI (instead of x-rays) to confirm correlative compressive spine lesions (Bono et al., 2011). An MRI should be considered for those who: 1) failed conservative therapy and who are candidates for interventional or surgical treatment; or 2) have severe or progressive neurologic deficits, or when serious underlying conditions are suspected (Onks & Billy, 2013; Bono et al., 2011).

An EMG-NCS can clarify functional capacities if the diagnosis of cervical radiculopathy is not clear. The NCS will evaluate for a peripheral neuropathy. The EMG can show changes which can identify a specific culprit anatomic level when imaging shows non-specific multi-level findings, although not until at least 3 weeks and not usually more than 52 weeks of a cervical radiculopathy situation (Chang & Date, 2009). EMG-NCS can help pre-operative planning, improve outcomes³³, and in the evaluation pre-employment function. Because of poor sensitivity, an EMG study should not be used to exclude a radiculopathy (Chang & Date, 2009).

EMG-NCS study should be considered if any of the following apply:

- Radicular symptoms of 3-52 weeks duration.
- Radiographic evidence of neural compression (“stenosis”) observed on MRI or CT scan, or marked narrowing of foramen on oblique radiographs.
- Physical exam results suggesting current radiculopathy or peripheral nerve entrapment/injury.

Candidates who experience any of the following should be restricted from physically demanding duties:

- Symptoms consistent with a cervical radiculopathy, and supported by the most recent MRI or EMG-NCS findings.
- Current activity-limiting neck or arm complaints.
- History of cervical laminectomy without fusion.
- History of transient quadriplegia-paresis, or more than one “stinger”, if there is ligamentous instability, disc disease with cord compression, significant spine degenerative changes, MRI evidence of spinal cord defect, more than one recurrence, or neurological findings lasting more than 36 hours.
- Current cervical instability on the basis of flexion and extension radiographs, or CT/MRI.

Chronic non-limiting cervical pain that is EMG-NCS negative is not considered sufficiently dangerous to warrant restrictions. However, for the pain to be considered non-limiting, the candidate should be currently participating in activities/sports of equivalent intensity to those required for physically-demanding peace officer job functions.

In certain cases of very recent neck pain, temporary deferral (<3 months) is recommended to determine the course of the condition and to allow healing. The severity and duration of the pain and the candidate’s current activity level should determine the length of the deferral period.

2) Lumbar Pain, Radiculopathy, and Spine Surgery

a. General Considerations:

Many of the considerations discussed in connection with the cervical spine apply to the evaluation of the lumbar spine. The focus of the lumbar evaluation should be on assessing the risk of sudden incapacitation during a critical incident. Such an incident could involve carrying an unconscious person, pushing a 3000 lb. car, jumping down from a 6 foot wall, or subduing an arrestee. Certain candidates are at substantially increased risk of acute neurological compromise of a leg (Weber, 1990), or more commonly, incapacitating acute spasm or pain of the lumbar musculature and region.

A back injury in peace officers typically result in less than two weeks of restricted duty; the median being four days (Sullivan, 1991). However, there is a frequent occurrence of longer-term disability that often develops after on-duty back injuries (Benoist, 2002). Sullivan and his colleagues (1988, 1991) found that 21% of 42 back-injured peace officers remained on restricted duty for three months or more. This rate of chronic disability is comparable to other types of workers, who typically

report an 80-90% return-to-work rate at three months post-injury (Nguyen & Randolph, 2007).

It is difficult to identify those who are either at significantly increased risk of sudden incapacitation or who have a high probability of developing chronic disability, due to the following considerations:

- Back pain is a part of life: About two-thirds of the adult population will experience low back pain. A specific anatomical diagnosis is made in only ~15% of cases (Deyo & Weinstein, 2001).
- Approximately 25% of asymptomatic adults have a substantial lumbar abnormality as revealed by MRIs. For those between 20-59 years old, 22% show disc herniation or spinal stenosis (Boden, Davis et al., 1990; Borenstein et al., 2001). In the Borenstein et al. (2001) study, there was no difference in prevalence between 20-39 year-olds and 40-59 year olds; however, Jensen et al. (1994) found prevalence to rise with age among those under 60 years old. Disc herniations (protrusions) were present in 21% of 20-39 year olds (Jensen et al., 1994) and 31% of 40-59 year olds. Approximately 7% of individuals had central canal stenosis and 7% had neural foramen stenosis; however, these findings were not age-stratified. Only infrequently was the presence of a frank disc extrusion or sequestration detected in asymptomatic individuals.

b. Restrictions:

The following criteria apply to candidates with < Grade III spondylolisthesis or < 45 degree scoliosis²:

- **Symptoms consistent with a lumbar radiculopathy and supported by the most recent MRI or EMG-NCS findings:** MRI is routinely used to confirm the diagnosis of radiculopathy, characterize the type of underlying lesion, and evaluate anatomy when symptoms are very severe. MRI is quite sensitive but may not be specific, making it a good screening test to identify possible causative pathology (Chang & Date, 2009). However, imaging should not be requested unless candidates are potentially considering an intervention, such as surgery or an epidural steroid injection (Chou et al., 2007), for candidates with severe or progressive neurologic deficits, or when serious underlying conditions are suspected.

The needle EMG provides the most specific evidence that lumbar pathology has current clinical significance. However, its lack of sensitivity (Chiodo et al., 2007) precludes its use in detecting radiculopathy (Chang & Date, 2009), nor identifying the cause of a radiculopathy. Observation of abnormal spontaneous activity (e.g., positive sharp waves, fibrillation potentials) is the specific EMG finding of concern (Chang & Date, 2009). A minority of these candidates may present demonstrable impairment, such as leg weakness. In others, it is

² Spinal deformity (Scoliosis) and Spondylolisthesis are discussed in sections 3 and 4, respectively.

reasonable to assume that physical stress to the back during a critical incident could worsen the radiculopathy and result in acute impairment.

- **Current limitation of activity:** Candidates may have permanent or “prophylactic” restrictions against heavy lifting, prolonged sitting or other activities to prevent recurrence of their low back pain.
- **Spinal fusion:** The return to full contact activities after a lumbar spine fusion surgery is controversial. There is evidence that these individuals are able to function in very physically demanding environments, such as professional sports and the military (Li & Hresko, 2012; Schroeder et al., 2013; Molinari & Gerlinger, 2001). However, the majority of spine surgeons prohibit contact sports for one year post-operatively and prefer that their fusion patients never return to collision sports (i.e. football, ice hockey), gymnastics, wrestling, weight-lifting, skydiving or bungee jumping (Eck & Riley, 2004; Rubery & Bradford, 2002). Approximately 80% of those in the military returned to full duty at four months, while 20% remained on permanent restrictive duty-limitations (Molinari & Gerlinger, 2001).

Low Back Risk Factors

Numerous studies have examined the predictive value of various low back pain risk factors; however, reliable conclusions are made difficult due to differences in outcome parameters and patient characteristics (e.g., occupational/recreational activity levels). Additionally, many risk factors are intercorrelated, such as muscle weakness and prior back injury (Nordgren et al., 1980; Hellsing & Brygeisson, 2000; Knapik et al., 2011). That notwithstanding, positive predictors include previous back pain episodes, high physical demands of work, low job satisfaction, age, back weakness, and smoking, (Deyo & Weinstein, 2001; Waddell & Burton, 2001; Latimer et al., 1999). Care seeking and disability due to chronic low back pain depend more on psychosocial issues than on individual clinical features or workplace physical demands (Waddell & Burton, 2001). Identifying and addressing these psychosocial factors improves outcomes and limits costs (Chou et al., 2007).

The following criteria are recommended for deferring certain candidates:

- Recent episode of back pain: A recent episode of back pain is a very strong predictor of future episodes. The rate of recurrence depends on how “recurrence” is defined (i.e. lost work days, a doctor’s visit, or symptom self-report) (Stanton et al., 2011; Kamper et al., 2011; Marras et al., 2007).

The majority of individuals with back pain and sciatica recover from an acute episode in 4-8 weeks (Hicks et al., 2002; van Tulder et al., 2006; Benoist, 2002). Approximately 80-90% return to work within 12 weeks post injury (Nguyen & Randolph, 2011). However 25-80% of those with low back pain experience some form of recurrent back problem in the following year (Hicks et al., 2002; van Tulder et al., 2006; McIntosh & Hall, 2011; Axen & Leboeuf-Yde, 2013). As many as 33% of these individuals have moderate intensity pain, and

15% have severe pain (McIntosh & Hall, 2011).

Based on these studies, candidates with a recent history of acute, work-limiting low back pain within the past year should be deferred until they have been asymptomatic for at least 6 - 12 months. The length of deferral should be based on an individualized assessment of relevant factors such as the duration of pain, the functional impact of the injury on activities, evidence of underlying degenerative disease, and current activity levels.

- Current back pain: The most predictive risk factor of future back pain is the presence of current back pain. Green et al. (2001) found that varsity college athletes with current pain had a 6-fold increased risk of sustaining a low back injury³ in the following year. Similar conclusions were reached in studies involving aircraft employees (Bigos et al., 1991) and army airborne soldiers (Schneider et al., 2000). Therefore, candidates with current back pain warrant indefinite deferral unless they have a long and current history of engaging in physical activities equal or greater in strenuousness to the essential job functions.
- Recent lumbar disc surgery: Disc surgery to treat the condition of non-specific low back pain (without sciatica) has a success rate ranging from 40-65%, with associated morbidity (Zigler et al., 2007), but disc surgery specifically treating herniated discs associated with sciatica offers better short-term outcomes than non-operative treatments. For instance, discectomy for sciatica produces 6-24 month outcomes with “good or excellent” results in 65%-90% of individuals, as compared to 36% of those who did not have surgery. The surgery may provide faster relief from acute sciatica, although any positive or negative effects on the long-term natural history of the underlying disc disease are uncertain (Gibson & Waddell, 2007; Weinstein et al., 2008).

Four years after lumbar spine surgery for a herniated disc, 85% of individuals resume working, as compared to 78% for those without surgery (Weinstein et al., 2008). Reoperation within one year occurred in 6% and increased to 10% at four years following surgery. About half of these reoperations were due to recurrent herniations at the same level. The 10-year discectomy results show significant improvements as compared to non-surgical treatments (Atlas et al., 2005). After surgery, 70% report symptom relief and satisfaction and 56% report the pain is “much better” or “completely gone”. However, as indicated in these results, many fail to experience complete pain relief.

Research on athletes who have undergone spine surgery is of particular relevance, given similarities between that group and peace officers with respect to population characteristics and physical demands. In a study of 171 professional athletes with a herniated disc, following microdiscectomy surgery, 89% returned to sport within six months, although 9% retired from their sport completely (Watkins et al., 2012). In another study, 87 National Hockey

³ A back injury was defined as pain causing an athlete to miss or only partly participate in at least three practice sessions or competitions, and that resulted in a visit to a sports physician.

League players with lumbar disc herniation had an 85% return-to-play rate regardless of the type of treatment (discectomy, fusion, or nonsurgical). However, player performance decreased compared with preinjury levels (Schroeder et al., 2013).

Most athletes return to full unrestricted play after resolution of pain and restoration of lumbar range of motion. Typically, all athletic activity is stopped post-operatively for at least two months, or until the individual can achieve painless lumbar extension. After microdiscectomy or laminectomy surgery, a full return to contact sports is expected to require ~3 months, although some guidelines advise 4-6 months. Athletes with current neurologic symptoms should be restricted from contact and collision sports. In the military, service members can return to unrestricted full duty at six months after a lumbar total disc replacement (TDR) if they have motion preservation, no instrumentation complications, and a resolution of preoperative symptoms (Li & Hresko, 2012). Some athletes with a spinal fusion are allowed to return to contact sports (Li & Hresko, 2012; Schroeder et al., 2013), but this is not without controversy (Eck & Riley, 2004): most spine surgeons advise against a return to contact and collision sports for athletes with a history of lumbar spinal fusion (Rubery & Bradford, 2002).

- Recent lumbar laminectomy is generally a two or three level surgery for lumbar spinal stenosis, generally with middle-age to geriatric patients (Weinstein et al., 2010). A good clinical outcome depends on sufficient nerve root decompression, minimum resection of facet joints to maintain spinal stability, early surgical intervention before severe paralysis becomes apparent, and postoperative trunk muscle exercises (Iguchi et al., 2000). Most U.S. spine surgeons advise ~4 weeks of a soft brace, and many make no brace recommendations at all. Some surgeons advocate for decompressive laminectomy in combination with instrumented fusion when treating lumbar stenosis with spondylolisthesis (Bassewitz & Herkowitz, 2001; Kornblum et al., 2004).

Long-term studies (4- and 7-year follow-up) on lumbar spinal stenosis show substantial pain, function, and disability improvements with decompressive laminectomy surgery, and little evidence of harm (Weinstein et al., 2010; Iguchi et al., 2000; Kornblum et al., 2004). Reoperation rates are 8% at two years, and 13% at four years. Compared to non-operative treatment, surgery provides more relief from bothersome back and leg symptoms, greater overall satisfaction with current symptoms, and higher self-rated progress. However, by 13 years after surgery, 15-20% of individuals show symptom deterioration. In a prospective study of 32 postal workers who had a lumbar laminectomy prior to hire experience a back injury rate six times higher than normal (Ryan & Zwerling, 1990a; Ryan & Zwerling, 1990b). Furthermore, these back injuries resulted in either repeat surgeries or retirement in 50% of eight cases. The median lost time was 66 days, compared to 8.5 days for back injuries in other employees. The median interval between surgery and hire was 6.5 years. Unfortunately, the operative indications, workup, any patient co-morbidities,

prior treatments, operative technique, and post-operative course were not specified or controlled.

The above research provides strong support for the deferral of post-surgical candidates until they have performed intensive occupational or recreational activities without symptoms for at least six months post-operatively (microdiscectomy and laminectomy patients), and at least 12 months for post-operative fusion patients. Most spine surgeons advise against a return to contact and collision sports for their athletes with a history of lumbar spinal fusion (Rubery & Bedford, 2002).

c. Recommended Evaluation Protocol:

Candidate history must be sufficiently thorough to establish the extent to which the candidate has experienced periods of lumbar pain, radicular symptoms, medication use, and/or limitation of activities. The candidate's current and recent activities (both occupational and recreational) should also be reviewed.

A review of medical records should confirm the candidate's history, especially if there is a history of litigation. The results of previous diagnostic tests such as an MRI, CT, or EMG-NCS should be obtained.

Candidates with a history of low back pain should have a complete back examination, including the tests described in Section II.A.2., hip range-of-motion looking for restrictions and groin pain, and a complete neurological examination of the lower extremities.

GROUP I: No history of significant back pain, radicular symptoms, limitations or lumbar spine surgery in the last three years

No restrictions or further evaluation (including radiographs) are necessary unless the physical exam is abnormal.

GROUP II: Not meeting criteria for GROUP I

A standing AP and lateral radiographs should be obtained if there is a history of chronic or recurrent pain in the last three years. Oblique views are not usually necessary, but can be helpful in equivocal cases of suspected spondylolysis⁷⁷. Standing lateral flexion-extension views to evaluate mobility can help in cases of spondylolysis, spondylolisthesis or previous spine surgery. Existing radiographs should be obtained if possible, as repeat x-rays expose the candidate to additional radiation and adds expense. Full body (skull to foot) films commonly performed by chiropractors are not sufficiently diagnostic to be useful.

Guidelines from the North American Spine Society consider MRI the most appropriate diagnostic test to confirm the presence of lumbar disc herniation for individuals with back pain and radicular pain (Kreiner et al., 2014). The American Pain Society and American College of Physicians suggest an LS Spine MRI for

individuals: 1) who have failed conservative therapy and who are candidates for interventional or surgical treatment, or 2) with severe or progressive neurologic deficits, or when serious underlying conditions are suspected (Chou et al., 2007).

An EMG-NCS can provide additional information to complement the history, physical exam and diagnostic imaging, if the diagnosis of a lumbosacral radiculopathy is not clear. Because of poor sensitivity, an EMG study should not be used to exclude a radiculopathy (Chang & Date, 2009). In general, an EMG-NCS is usually not that helpful in the diagnosis of lumbar radiculopathy (Cho et al., 2010; Kreiner, 2014), unlike the case in cervical radiculopathy presentations (Chang & Date, 2009).

EMG-NCS study could be considered if any of the following apply:

- Radicular symptoms of 3-52 weeks duration.
- Radiographic evidence of neural compression (“stenosis”) observed on MRI or CT scan, or marked narrowing of foramen on oblique radiographs.
- Physical exam suggesting current radiculopathy or peripheral nerve entrapment/injury.

Any of the following would preclude the ability to perform heavy lifting, jumping off walls, subduing arrestees or other physically-demanding job duties:

- Most recent MRI and/or EMG-NCS evidence is consistent with a lumbosacral radiculopathy.
- Current symptoms that limit activity, or the absence of a well-established activity level similar in strenuousness to the physical demands of a peace officer.
- A history of lumbar spine fusion surgery (Eck & Riley, 2004; Rubery & Bradford, 2002; Nordgren et al., 1980), unless the candidate’s activity level is equivalent to the physical demands of a peace officer, and who has been problem-free for a considerable period of time (Schroeder et al., 2013; Molinari & Gerlinger, 2001).

Temporary deferral (generally 6-12 months) may be recommended if:

- The candidate has recovered from an episode of back pain within the last year. The length of deferral should be based on an individualized assessment of relevant factors, such as the duration of pain, the functional impact of the injury on activities, evidence of underlying degenerative disease, and current activity levels.

- Recent lumbar spine surgery. The length of deferral should be based on the surgeon’s recommendations, when the candidate recovered from surgery, and recent engagement in activities equivalent to that of a peace officer and for how long.

3) Spinal Deformity (Scoliosis)

a. General Considerations:

The most common spinal deformities occur in the coronal and sagittal planes, usually accompanied by a rotatory component in the horizontal plane. Distortions greater than 10° in the coronal plane result in a deformity known as scoliosis Grob et al., 2008). Angle measurements <25° are classified as “mild” deformity. Idiopathic adolescent scoliosis is the most common form, but there are more than 10 subsets of structural scoliosis and additional forms of apparent scoliosis (e.g. from a leg-length discrepancy).

Scoliosis can cause chronic pain, radicular symptoms, and restriction of lung volumes, the majority of patients are asymptomatic; however, back pain with scoliosis appears with a frequency similar to the general population (Weinstein et al., 2008). Scoliosis does not cause excessive pain or disability, and individuals work and participate in everyday activities similarly to the general population (Weinstein et al., 2008). Nevertheless, the clinical presentation of adult scoliosis can vary greatly, ranging from minimal or no symptoms, to severe pain and marked disability (Schwab et al., 2007), especially for individuals with apical rotation, imbalance and curves greater than 45 degrees (Kostuik, 1990). When symptomatic, the complaints vary from mild back pain to severe back pain with sciatic features and limited walking ability (Youssef et al., 2013).

Although adult scoliosis is relatively common, the many unique and complex patterns of curvature have made characterization difficult, making it difficult to predict the effect of spinal deformity on health status based on radiographic parameters alone (Glassman et al., 2005). A history of scoliosis-related back pain is not related simply to curve magnitude, vertebral level of deformity, the presence or absence of osteoarthritis on x-ray, or whether a caudal fusion level stops at L5 or at the sacrum (Weinstein et al., 2008; Sardar et al., 2013).

In a large, heterogeneous population of adults with scoliosis, the most important predictor of pain and function was sagittal balance rather than major curve location and magnitude, apical vertebral rotation, rotatory subluxation or coronal shift (Glassman et al., 2005). Age and thoracolumbar deformity (instead of thoracic-only deformity), pelvic tilt and range of hip extension motion appear related to disability. The complex relationship between spinal alignment, balance and function is demonstrated by adults who are treated surgically, where the largest improvements are seen for corrections to introduce lumbar lordosis, improve subluxation and improve sagittal balance (Schwab et al., 2007).

Approximately 2% of scoliotics have radicular pain symptoms due to nerve root entrapment from facet joint hypertrophy and/or vertebral spur encroachment into the foramen (Kostuik, 1980). However, facet joint sclerosis on radiograph does not significantly increase the probability of pain in general (Kostuik & Bentivoglio, 1981).

Cardiopulmonary problems rarely arise in adolescent idiopathic scoliosis, although large thoracic curves (>50 degrees) have been associated with reduced vital capacity and shortness of breath sacrum (Weinstein et al., 2008).

Estimating curve progression is complicated. Idiopathic scoliosis progress is closely related to maturity factors (i.e. age, height, weight, skeletal and sexual maturation), as well as the spinal region, the spinal curve acceleration history Sanders et al., 2007) and genetic polymorphism (Wong & Tan, 2010). Curves do not necessarily stop progress after skeletal maturity, particularly larger magnitude curves with rotation of the apical vertebra. However, after skeletal maturity, curves <30 degrees generally do not progress, and larger curves progress very slowly (Kostuik, 1979). Thoracic curves >50 degrees progress an average of one degree/year, while others progress an even lesser amount (Weinstein & Ponseti, 1983). In the aging spine, curve progression are affected by osteoporosis, fracture and degenerative arthritis (Aebi, 2005). Due to the difficulty accurately measuring angles, a diagnosis of curve progression requires a change of at least 10 degrees (Weinstein et al., 2008). The threshold curvature for determining the need for surgical correction is a Cobb angle between 40-50 degrees (Weinstein et al., 2003).

Scoliosis may be treated surgically, using instrumentation with pedicle screw fixation or various anterior systems degrees (Weinstein et al., 2008; Aebi, 2005). Considerable progress has been achieved in the ability to surgically correct in multiple anatomical planes, the use of more stable fixation devices, reduction in the number of fusion levels, and the avoidance of postoperative brace/cast immobilization. For adolescents, the primary objectives of surgical treatment are to arrest curve progression, achieve maximum correction of deformity in three dimensions, improve appearance, and minimize short and long-term complications. In adults, the surgical indications are curve-related pain unresponsive to non-operative management, curve progression, and symptoms arising from spinal degeneration. Technology has greatly increased the safety of surgical management to correct spinal deformity and preserve spinal balance. Surgery appears to improve quality of life, pain and disability; however, it does not alleviate all symptoms, nor does it restore function to a level comparable to non-scoliotic individuals. Moreover, the long-term results of the evolving surgical methods as compared to non-operative treatments are not yet fully established (Lykissas et al., 2013)

Those who underwent scoliosis surgery from the 1970-80s may have had placed antiquated spinal fixation systems, such as Harrington rods. Those who underwent surgery in the 1990s may have Coutrel-Dubousset instrumentation. For the most part, the long term physical outcomes following such surgeries are good, with 80% of Harrington rod patients reporting no or only occasional low back pain in long term (17 year) follow-up (Bas, Franco, & Bas et al., 2012). However, these individuals do

report significantly decreased psychological health status (Gotze et al., 2002) and higher risks of complications resulting in revision surgery (Lykissas et al., 2013; Remes et al., 2004; Anand et al., 2013).

Only one published study has addressed activity following spinal fusion for scoliosis. Based on a survey of Scoliosis Research Society (SRS) members, low impact, noncontact sports are allowed at six months post-operatively (Rubery & Bradford, 2002). The SRS definitions of “contact” and “collision” sports differ slightly from the formal definitions provided by the American Academy of Pediatrics, who do not separate contact from collision sports (Rice, 2008). At one year post-operatively, the SRS allows participation in contact sports such as basketball, soccer and baseball. Most SRS members advised against or prohibit participation in sports such as wrestling, American football, ice hockey, gymnastics, sky diving and trampoline.

b. Recommended Evaluation Protocol:

Candidates should be asked about signs of curve progression, such as decreasing height or increasing dorsal “hump” on flexion. A thorough exercise history, both recreational and occupational, should be conducted. A complete back examination should include the tests described in General Screening Recommendations (Section II.A.2). Candidates with curves of ≥ 25 degrees (Koumbourlis, 2008) should undergo pulmonary function tests and should be evaluated per the procedures outlined in the Respiratory Chapter.

Complete medical record review should include previous back x-rays to assess progression. The best view to assess curve angles is from a standing AP and lateral, full-length (3') spinal x-ray, taken with the arms positioned in 30 degrees of shoulder flexion (Blondel et al., 2013; Morrissy et al., 1990).

GROUP I: Curve < 45 degrees

Evaluate per the Recommended Evaluation Protocol for Lumbar Pain, Radiculopathy, and Spine Surgery (Section II.B.2.c.).

GROUP II: Curve ≥ 45 degrees

Level 1 – No history of radiculopathy at any time and no limitation of recreational or occupational activities in the last year

Candidates younger than 35 years old with significant curve progression (>10 degrees) should be deferred until seen by a spine surgeon for possible surgical correction. However, the probability of progression is not high enough to warrant deferral during a "prospective" observation period.

Candidates who engage in strenuous activities equivalent to that of a peace officer, and experience no more than mild discomfort, do not require deferrals or restrictions. However, candidates who do not subject their backs to strenuous

activities should be deferred due to the risk of moderate to severe pain and risk of activity limitations due to cardiopulmonary restrictions.

Level 2 – Does not meet criteria for Level 1

These candidates should be restricted from heavy lifting, wrestling and other strenuous activities due to the increased risk of sudden incapacitation from pain.

GROUP III: History of fusion surgery for scoliosis

Flexion-extension radiographs and a CT to evaluate fusion should be ordered (Gruskay et al., 2014). An MRI with contrast and a metal artifact reduction sequence can help evaluate the neural elements and detect evidence of scar tissue, disc bulge, arachnoiditis and other issues (infection, edema) particularly within the first year after a surgery (Lee et al., 2007). Both CT and MRI are susceptible to metal artifacts. In questionable cases, a CT myelogram and an EMG-NCS study may be necessary.

Level 1 – Candidates without the findings indicated below for Levels 2 & 3

These candidates should be restricted unless they are currently engaged in activities of equivalent rigorousness to peace office job demands and have been doing so for a considerable period of time without problems.

Level 2 – Candidates with positive neurological signs or symptoms, compression of neural elements documented by MRI or EMG, or more than 30% stenosis of the central spinal canal.

A substantial risk of serious injury from strenuous activities renders these candidates are not suitable.

Level 3 – Unstable fusions, evidence of pseudarthrosis, or instrumentation failure.

Defer for consultation with a spine surgeon.

4) Spondylolisthesis

a. General Considerations:

The most common causes of spondylolisthesis are facet joint arthritis (degenerative) and pars defects related to repetitive trauma and mechanical stress (isthmic) (Pathria, 2008; van Tulder et al., 2006).

In 90% of degenerative cases, L4 slips forward on L5. There is a favorable natural history for degenerative spondylolisthesis: only 10-15% of patients who seek treatment eventually opting for surgery (Vibert et al., 2006).

In 90% of isthmic cases, the L5 vertebra slips forward on S1. Pars defects (spondylolysis) typically develop between the ages of 5-15 years old. Only 2-10% of adults are affected and the majority of these are not symptomatic^{77, 107}. The incidence of low back pain in adults with Grade I and II isthmic spondylolisthesis is similar to that of the general population (Jones & Rao, 2009; Beutler et al., 2003).

Spondylolisthesis can be graded according to the degree of slip over the underlying vertebral body below, best seen on lateral x-rays or CT scan:

- Grade I - 25% or less
- Grade II - 26-50%
- Grade III - 51-75%
- Grade IV - 76-100%
- Grade V - >100%, also termed “spondyloptosis”

Neither spondylolysis nor Grade I or II spondylolisthesis are major risk factors for lumbar disability (Apel et al., 1989). Grade I slips are usually asymptomatic. However, subjects with Grade II or higher slips may complain of back pain, usually without radicular leg pain (Chang et al., 2008). When symptomatic, back pain may be aggravated by lumbar extension or weight-bearing activities, such as running or jumping. MRIs may show reactive bone marrow changes indicative of a subacute stress fracture in the posterior bony elements of the vertebral body. In cases of suspected acute spondylolysis, a three-phase bone scan with single-photon computed tomography (SPECT) images may be more sensitive to demonstrate fractures, especially for those that are subtle (Pathria, 2008). Radicular symptoms may occur due to stretching of nerve roots over the posterior sacral body in the case of more significant spondylolisthesis, or nerve compression from an associated disk protrusion or narrowed neuroforamen.

There is a general consensus that children and adolescents with isthmic slips of 50% or greater have a poor non-operative prognosis and are likely candidates for surgery (Agabegi & Fischgrund, 2010). In contrast, adults with high-grade slips often achieve a stable position without further slip progression. Some of these adults are asymptomatic or minimally symptomatic. In general however, athletes with grade III or IV spondylolisthesis are advised against high speed and contact sports (Chang et al., 2008).

Surgical fusion may be indicated for those whose pain is not relieved by non-operative measures (Agabegi & Fischgrund, 2010; Rainville, 2004; Weinstein et al., 2009). Compared to nonsurgical care, spine surgery offers significant benefit for those enduring a combination of unremitting pain and the presence of progressive neurological symptoms, cauda equina syndrome, radiographic progression to greater than grade II spondylolisthesis, or symptomatic grade II and higher spondylolisthesis (Alfieri et al., 2013; Jones & Rao, 2009; Vibert et al., 2006).

A return to activities requiring physical contact after lumbar fusion surgery for spondylolisthesis is controversial (Li & Hresko, 2012; Eck & Riley, 2004). A return to contact sports (i.e. basketball, soccer) may be allowed one year after fusion surgery; some individuals with fusion surgery are able to return to very physically demanding environments such as professional ice hockey and the military (Schroeder et al., 2013; Molinari & Gerlinger, 2011). However, the majority of spine experts suggest those who undergo spondylolisthesis fusion to never return to collision sports (i.e. boxing, football, ice hockey), bungee jumping, rugby, skydiving, wrestling, or weight-lifting (Rubery & Bradford, 2002).

Spondylolithesis may be treated with decompressive laminectomy without fusion surgery in some situations (Weinstein et al., 2009; Vibert et al., 2006; Epstein, 1998), but decompression with fusion is more standard. Activity restriction after a decompression-alone surgery for spondylolisthesis is generally more conservative, and made on an individual basis, but no widely-held published recommendations are available regarding vigorous activity.

b. Recommended Evaluation Protocol:

Candidates with a history of spondylolisthesis require a complete back examination involving the tests described in General Screening Recommendations, Section II.A.2. Lumbar spine range of motion usually is normal but occasionally there is hypermobility (Vibert et al., 2006). Palpation may reveal a step-off at the level of the spondylolisthesis. A complete neurological examination of the lower extremities is necessary despite results that are often normal or nonspecific (Vibert et al., 2006). Standing lateral flexion-extension x-ray views to evaluate lumbar mobility help facilitate the protocol described below (Pathria, 2008). If neurological symptoms are present, a lumbar spine MRI should be performed.

GROUP I: Spondylolisthesis <25% (Grade I)

This does not represent a significant risk factor for future recurrences. Candidates with a history of pain should be evaluated per the procedures in Lumbar Pain Section II.A.2).

GROUP II: Spondylolisthesis 26-50% (Grade II)

Candidates with Grade II or higher slips may complain of back pain, usually without radicular leg pain (Chang et al., 2008).

Level 1 – No history of back pain

These candidates should be cleared regardless of the x-ray findings.

Level 2 – Positive history of back pain

Evaluate per the procedures in Lumbar Pain II.A.2. However, the presence of an underlying structural abnormality should be considered an independent risk factor

for recurrent back pain. Lumbar spine surgery may be indicated for those whose pain is not relieved by non-operative measures (Rainville, 2004; Weinstein et al., 2009; Vibert et al., 2006; Jones & Rao, 2009).

GROUP III: Spondylolisthesis greater than 50% (Grade III+)

These candidates are commonly unable to perform rigorous physically-demanding activities without pain (Chang et al., 2008; Watkins & Dillin, 1990). However, candidates in their late twenties or thirties with a documented record of heavy exertion over a number of years without significant back pain or radiculopathy may be cleared (Kasliwal et al., 2013; DeWald et al., 2005).

5) Miscellaneous Lumbar Spine Conditions

The following lumbar spine abnormalities (often discovered on routine imaging) with limited prognostic value should generally be ignored:

- Abnormal lumbar lordosis (Christensen, & Hartvigsen, 2008).
- Scheurmann disease (van Tulder et al., 1997).
- Schmorl's nodes (Mattei & Rehman, 2014; Kyere et al., 2012; Wang et al., 2012).
- Spina bifida occulta (van Tulder et al., 1997).
- Spondylolisthesis (grade I) (Pathria, 2008; van Tulder et al., 1997).
- Tarlov cysts (Lucantoni et al., 2011).
- Transitional vertebrae (Bron et al., 2007; van Tulder et al., 1997).

Spinal cord stimulators. Post-surgical spine patients who have tried chronic opioid therapy yet remain with chronic neuropathic pain may resort to spinal stimulator implantation for pain management (North & Linderoth, 2010). These candidates can be presumed incapable of engaging in physically-demanding job duties.

6) Meniscal Injuries

a. General Considerations:

The menisci are soft C-shaped structures on the medial and lateral sides of the knee that assist with shock absorption, load transmission, joint stability, joint nutrition, and joint lubrication. The menisci also have a significant role in neuromuscular control of the knee, providing proprioceptive information regarding joint awareness such as position, direction, velocity, acceleration and deceleration (Gray, 1999; Nyland et al., 1994). The meniscus can tear as a result of a sudden twist or turn, usually with the knee in flexion (bent), or as a result of chronic overuse. Symptomatic meniscus tears cause pain and tenderness along the medial or lateral joint line. Significant, unstable or flap tears may cause mechanical symptoms, such as catching or giving way due to pain. Bucket-handle tears (involving a large piece of meniscus that displaces centrally within the knee) may

actually cause the knee to lock, requiring manual maneuvering to straighten the knee.

A meniscus tear often necessitates work restrictions due to pain, swelling, stiffness, and mechanical symptoms such as locking or catching. Some smaller, more chronic tears may be better tolerated, especially in the setting of degenerative joint disease.

Symptoms and Signs: The most common complaint with a meniscal tear is pain. Pain is generally specific to either the medial or lateral joint line, depending on the side of the tear. The diagnosis is suspected if there is a typical history of injury, or history of swelling, locking, giving way, or joint line pain. On examination, classic findings include a joint effusion, joint line tenderness and a positive McMurray test (Figure VIII-3). Individuals often have difficulty with duck walking or going into a full squatting position. The diagnosis is confirmed with MRI scan.

Imaging: The MRI is the preferred imaging modality for identifying meniscus tears, with ~90% sensitivity and specificity (Van Dyck et al., 2007). Radiographs may also be obtained to rule out osteoarthritis (seen as joint space narrowing and osteophytes) in those over 40 years old. Standing AP and lateral views are recommended. IV contrast and dye arthrogram are generally not necessary for the accurate diagnosis of a meniscus tear. However, an MRI arthrogram can be helpful in cases of prior meniscal surgery (Sahin & Demirtas, 2006; Mohankumar et al., 2014). The MRI can define the size and type of meniscal tear (degenerative, vertical, complex, bucket-handle) to guide treatment plans (Nguyen et al., 2014). Vertical “radial” tears, vertical longitudinal “bucket-handle” tears, and tears with a displaced flap (either horizontal or oblique) are more likely to require surgery (Laible et al., 2013).

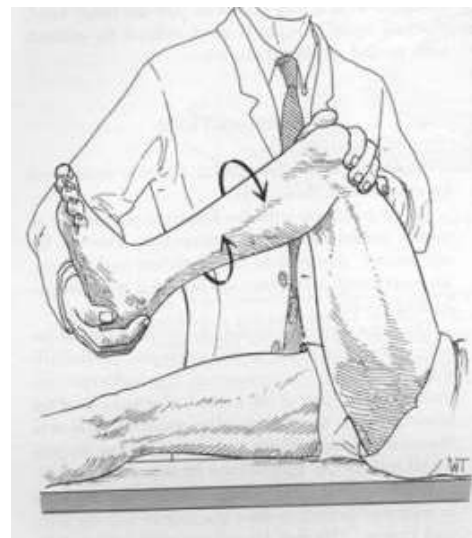

Figure VIII-3. McMurray Test

From Apley, AG. The diagnosis of meniscus injuries. *J Bone Joint Surg Am.* 1947; 29:78-84. Reprinted by permission of the publisher (<http://jbsj.org/>).

An early MRI can be helpful for those who complain of catching or locking, and whose McMurray test is positive. If a candidate has pain but minimal swelling without mechanical symptoms, non-operative treatment can be initiated. If this is not successful, advanced imaging should be considered.

Treatment: Not all tears are symptomatic. Treatment is guided by symptoms without concern for asymptomatic tears, particularly if they are degenerative in nature (Frizziero et al., 2012). Depending on the individual’s age, tear characteristics, and absence/presence of osteoarthritis, a meniscal tear can be managed non-operatively or surgically with either a repair or with a partial meniscectomy (partial removal). Tears >1 cm should be considered seriously for

surgery, but function and symptoms are the main determiners of whether surgery is warranted. Procedures to repair meniscus include inside-out, outside-in, open, and all inside repairs. The fixations vary from suture repairs to biodegradable devices.

Non-operative care can be initiated for candidates with minimal pain/swelling and no mechanical symptoms. Such care focuses on range of motion and functional rehabilitation, and possible bracing to unload the medial or lateral compartment. Non-surgical care may also be optimal for candidates with osteoarthritis, as many studies have shown limited improvement in function after knee arthroscopy in the setting of osteoarthritis with results comparable to nonoperative management.

Candidates with mechanical symptoms (catching or locking) or persistent pain and swelling often benefit from surgical treatment. Meniscal surgery is performed arthroscopically. Meniscal repair versus partial meniscectomy is based on individual factors, including the tear characteristics and the individual's age. Repair is preferred in younger individuals in order to preserve meniscal tissue, although this typically requires a more extensive recovery time.

In the immediate post-surgical period, physical therapy ensures returning range-of-motion and muscle strength to normal, as well as proprioception and functional rehabilitation. Neuromuscular rehabilitation and training is a key component of meniscus injury rehabilitation, with an emphasis on sport-specific neuromuscular control (Bizzini et al, 2006; Shelbourne, Patel, Adsit et al., 1996). Many surgeons limit squatting, agility drills, or full-speed running until three months following partial meniscectomy and six months following repair (Kim, Nagao, & Kamata et al., 2013; Shelbourne et al., 1996). Return to full activity is dependent upon full, pain-free ROM, satisfactory clinical examination, and satisfactory isokinetic test results for strength.

b. Recommended Evaluation Protocol:

Those who report a history of meniscal tear should be asked about any of the typical complaints found in Table VIII-1. Details regarding any surgical treatment and subsequent rehabilitation should be noted. The 16-question [Western Ontario Meniscal Evaluation Tool](#) (WOMET) is a well-validated patient survey to quantify and track the burden of meniscal injury symptoms (Wang et al., 2010).

In addition to the screening knee exam described in Section IIA, a complete examination of both knees should include:

Range of Motion: With the candidate supine and knees flexed, note any differences in heel to thigh distance. With the candidate prone and knees fully extended with feet hanging beyond the table, note any differences in heel height. Each centimeter difference represents one degree of extension deficit. A significant deficit is present when the knee cannot be flexed to at least 120°, or there is an extension deficit of 10° or greater (Mohtadi et al., 1991).

Thigh Circumference: Candidates with prior knee injury are at risk for ongoing symptoms related to incomplete rehabilitation. This is suspected when there is

significant muscle atrophy in the quadriceps or hamstrings. Isokinetic strength testing of the injured limb should be greater than 80-90% of the uninjured limb, and a side-to-side difference in thigh circumference should be no greater than 1 cm. prior to a return to full physical activity (Barber-Westin & Noyes, 2011a). Thigh circumference can be measured either at its maximal girth or at a standardized distance from the medial joint line (e.g. 15 cm.) with the leg at rest (Jarvela et al., 2002). Candidates with significant atrophy (i.e. a side-to-side difference >20% in strength, or >1 cm in circumference) may benefit from further rehabilitation prior to hire.

McMurray Test: see Figure VIII-3

Obtain records for candidates with abnormal physical exam and prior meniscus tear on MRI or prior surgery.

Evaluation Guidelines:

In general, a candidate is acceptable if they have resumed full and vigorous activity for at least three months without significant symptoms and who have a normal physical examination, regardless of the original pathology or treatment.

Candidates with joint line tenderness and a positive McMurray test should be re-evaluated by an orthopedist and considered for MRI.

Evidence of significant muscle atrophy, swelling/knee effusion, loss of motion, or decreased neuromuscular control warrants a referral for further assessment and possible rehabilitation. Either abnormality can limit peak performance during a critical incident and substantially increase the risk of knee pain and recurrent injury.

Table VIII-1. *Post-Operative Complaints in Patients Who Are Treated by Meniscectomy*

-
1. Stiffness of knee
 2. Swelling of knee
 3. Pain at rest and/or motion
 4. Feeling of instability
 5. Loss of strength associated with knee movements
 6. Giving way
 7. Normal participation in sports and/or hobbies impossible
 8. Disability climbing/descending stairs
 9. Disability kneeling
 10. Disability squatting
 11. Disability walking on uneven surfaces
 12. Inability to perform the same occupation as preoperation
 13. Change of occupation due to post-meniscectomy symptoms
 14. Locking
-

From Veth, R.P.H. 1985. Clinical significance of knee joint changes after meniscectomy. *ClinOrthop Rep Res.* 198:56-60. Reprinted by permission of the publisher.

7) Loose Body in the Knee

Intra-articular loose bodies are chondral, osseous or osteochondral fragments, as well as meniscal flaps, tears or extrusions, located in the joint cavity (Azer et al., 2004; Bianchi & Martinoli, 1999; Sansone & De Ponti, 1999; Froelich & Hillard-Sembell, 2009). Such a fragment can cause sudden locking or giving way due to pain and mechanical obstruction of the joint range-of-motion.

Radio-opaque osseous and osteochondral loose bodies are most commonly discovered on knee radiographs while evaluating for other pathology. Unstable loose bodies will move freely inside the joint and can become entrapped intermittently to cause symptoms at irregular intervals (Bianchi & Martinoli, 1999). Symptomatic loose bodies require surgical removal. Loose bodies that become attached to a fixed position to the synovial membrane or that maintain a constant location in a synovial recess are usually well tolerated and do not require surgery. The eight- question [Lysholm Knee Questionnaire](#) is a validated patient survey to quantify and track the burden of such symptoms (Wang et al., 2010).

Purely chondral lesions are radiolucent. However, most loose bodies have a radio-opaque, calcific component which are detectable with radiographs. With the initial set of films, it is often difficult to determine whether the object is adherent to soft tissue within the knee and therefore not of concern. Repeat radiographs after walking or repositioning can be helpful by showing movement of the object when it is a true loose body. If a loose body is suspected but not seen on radiographs, a cartilaginous loose body may be present and detectable using ultrasound, but is most reliably evaluated using MR imaging (Miller, 2009), or MR arthrography (Sahin & Demirtas, 2006). If a loose body is confirmed, should result in running and wrestling restrictions until it is removed, although exceptions could be made if prior radiographs document that the presence of the loose body for a number of years and the candidate has been asymptomatic. Loose bodies in the posterior part of the knee are less likely to cause symptoms.

Loose bodies can generally be removed arthroscopically. Post-operative rehabilitation focuses on control of swelling and pain and restoring normal range-of-motion, neuromuscular coordination, proprioception, strength and power. Expected return to full duty after loose body removal is 4-10 weeks. Cartilage defects found in association with a loose body should be closely monitored for ongoing symptoms and progression.

8) Patellofemoral Problems

a. General Considerations:

The patella and the patellar tendon transmit the extension force of the quadriceps to the proximal tibia. The normal angulation or valgus of the leg and the relative increased width of the hip versus the knee create a quadriceps angle ("Q" angle) between the quadriceps tendon above and the patellar tendon below the patella (Figure VIII-4). This results in a force vector which pulls the patella laterally.

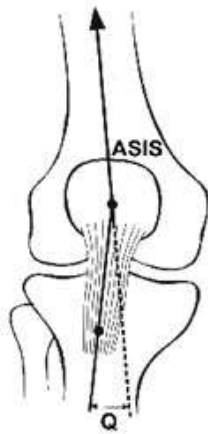


Figure VIII-4. Q-angle

<http://bestpractice.bmj.com/best-practice/monograph/827/resource/s/image/bp/1.html> Reprinted with permission from BMJ Publishing Group.

In the normal knee, this lateral force is opposed by a combination of static and active stabilizers. The static stabilizers consist primarily of the medial patellofemoral ligament (MPFL) and the trochlea or femoral groove between the femoral condyles. The MPFL is the primary restraint to lateral movement of the patella (Amis, 2007). The primary active stabilizer is the medial component of the quadriceps, the vastus medialis obliquus (VMO).

At full extension, the patella is slightly proximal and lateral to the trochlear groove. Between 0-20 degrees of flexion, the patella is smoothly and gradually drawn into the groove and is well-seated by 30 degrees. Once the patella is seated in its groove, dislocation is unlikely as there is generally bony stability. However, between 0-30 degrees, the dynamics of this movement require a balance between the lateral force vector and the medial stabilizers.

Several types of pathology may result around the patella. First, instability (dislocation or subluxation) may occur when there is disruption or increased laxity of these stabilizing forces. This may result in episodes of pain and loss of function with fairly normal function between episodes. Second, relative tightness of the lateral patellar retinaculum (soft tissues) coupled with bony malalignment can result in increased pressure on the lateral side of the patella. Lateral Patellar Compression Syndrome (LPCS) results in pain at the lateral aspect of the patella. Third and most common is Patellofemoral Syndrome, which presents as pain in the anterior knee without structural pathology. Finally, loss of cartilage under the patella can result in painful chondromalacia, or when more severe, patellofemoral osteoarthritis.

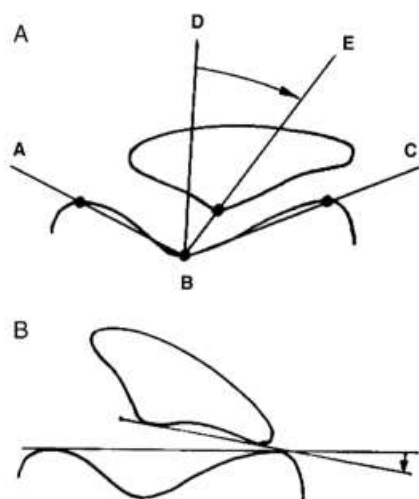
Patellar Instability

Subluxation commonly causes sensations of giving way and may cause the individual to stop what they are doing, at least temporarily (Eisele, 1991). Actions that typically precede subluxation include decelerating while walking down stairs, running, jumping, or twisting while putting weight on the affected leg. Subluxation can predispose to frank dislocation at any time, even with trivial injuries (Fulkerson, 2004). Dislocation is a dramatic, severe and incapacitating injury.

Patellar dislocations will often self-reduce. If the patella remains dislocated, reduction is achieved via gentle extension of the knee and medial-ward pressure on the patella. Swelling and pain result in most cases. Initial treatment involves RICE, bracing, and crutch use. When acute, individuals experience significant pain with active knee extension, tenderness along the medial retinaculum, an effusion, and “apprehension” with lateral movement of the patella. They may also demonstrate lateral movement of the patella during active extension of the knee (J-sign). In individuals who can’t actively extend their knee, significant patellar retinacular tearing should be considered.

Imaging: Following a first patellar dislocation, radiographs should be obtained to exclude fracture or loose body and to evaluate patellar alignment. In addition to the standard AP and lateral views, a bilateral merchant view taken at 30° should show the patella centered in the trochlea without excessive tilt or lateral translation. Multiple measurements can be taken on the merchant view to quantify patellar alignment and tilt (Figure VIII-5) (Amis, 2007; Colvin & West, 2008; Alaia et al., 2013). For those with persistent pain or a recurrent dislocation, an MRI is useful for evaluating MPFL integrity, patellofemoral cartilage damage, and patellar alignment, as well as excluding other injury. MRI can also identify a rare case of chondral loose bodies.

Patellar alignment is evaluated by tibial tubercle-trochlear groove (TT-TG) distance on an MRI or CT scan. A TT-TG distance >20 mm may indicate the need for a bony realignment procedure (Camp et al., 2013; White & Sherman, 2009), as would the presence of patella alta (Colvin & West, 2008). Although unnecessary in most cases, CT scans can be helpful when bony anatomy is abnormal; they can be performed kinematically with the knee at different angles of flexion to better assess tracking deficits of the patella.



A) Sulcus Angle is defined by points A-B-C.

Patellar Lateral Translation indicated by the positive congruence angle D-B-E

-Where DB bisects the sulcus angle A-B-C and BE passes from deepest point of the sulcus through the posterior-most point on the ridge of the patella.

B) Lateral Patellar Tilt is indicated by a negative Laurin angle.

Figure VIII-5. Patellar Measurements from the Merchant "Skyline" Radiographic View

From Amis AA. Current concepts on anatomy and biomechanics of patellar stability. *Sports Med Arthrosc.* 2007;15(2):48-56. Printed by permission of the publisher.

Treatment: A first patellar dislocation is generally treated nonoperatively (Stefancin & Parker, 2007). Fithian et al. (2004) found that only 17% of first-time dislocation patients presenting to the emergency room had recurrent instability at follow-up 2-5 years later. This argues for initial non-operative treatment with rehabilitation, focusing on VMO, hip, and core strengthening (Alaia et al., 2013). Individuals may return to activity in a patellar stabilizing brace once pain and swelling are resolved and quadriceps function is restored. Among those with a previous patellar subluxation/dislocation who present to the emergency room with an episode of dislocation, 49% had recurrent instability at 2-5 year follow-up (Fithian et al., 2004). In those few individuals who experience recurrent instability, surgery is required to stabilize the patella and allow normal function. The most important risk factor for ongoing patellar instability is previous instability; however, other risk factors, such as female gender, generalized ligamentous laxity, and valgus alignment at the knee, must also be considered.

For those with normal alignment and bony anatomy, MPFL reconstruction is the most common surgical procedure (Colvin & West, 2008; White & Sherman, 2009). This procedure recreates the MPFL ligament, the key restraint to lateral translation of the patella. Medial quadriceps tendon–femoral ligament (MQTFL) reconstruction is an alternative procedure, with a reduced risk of patella fracture, a known and serious complication of MPFL reconstruction (Fulkerson & Edgar, 2013). In individuals with elevated TT-TG or trochlear dysplasia (flat trochlear groove), a bony realignment such as a tibial tubercle osteotomy may be indicated.

Lateral Patellar Compression Syndrome (LPCS):

LPCS occurs due to excessive tightening of the lateral soft tissue or retinaculum of the patella, or bony malalignment resulting in increased pressure on the lateral patellar facet. The resulting pain is centered on the lateral side of the patella. Pain is generally worse with exercise and stair climbing. Examination will often demonstrate normal patellar tracking. True instability is not present with LPCS. Patellar tilt may be observed on exam and often the examiner will be unable to correct the patellar tilt to normal flat alignment. Tightness of the iliotibial band (ITB) is often associated with LPCS and may be detected using the Ober test. Because the ITB has attachments to the lateral retinaculum and to the patella, it has a significant effect on patellar position, tracking, and pain, especially when it is excessively tight.

Imaging: Radiographs will show increased patellar tilt on the merchant view. An MRI is generally not necessary for diagnosis, but may be helpful in evaluating patellar chondral loss or excluding other diagnoses.

Treatment: LPCS is treated initially with physical therapy to stretch the lateral retinaculum, ITB and other lateral structures, as well as strengthening of the hip/pelvis and core musculature. Taping of the patella (“McConnell” technique) can modify patellar tilt until the soft tissues are rebalanced (McConnel, 1986). This is sufficient in most cases. In some individuals, pain persists and arthroscopy with lateral release (of the patellar retinaculum) may be necessary.

Patellofemoral Syndrome (PFS)

Patellofemoral pain syndrome is the most common overuse injury of the lower extremities, accounting for about 25% of knee injuries diagnosed in sports medicine clinics (and even higher incidence rates among females) (Devereaux & Lachmann, 1984; DeHaven & Lintner, 1986; Taunton et al., 2002). PFS leads to reduced physical activity and quality of life. For many, PFS is a chronic problem with persistent clinical symptoms (Stathopulu & Baildam, 2003; Wills et al., 2004; Kannus et al., 1999).

Patellofemoral Syndrome is defined as pain at or under the patella without structural abnormality. It may affect one or both knees and can be quite disabling. Symptoms tend to be worse while climbing/descending stairs or hills and during exercise. Some individuals also report pain with prolonged sitting (“movie/theatre sign”). Swelling is generally not present. Catching or giving way may be reported.

This is generally not true mechanical instability (patellar dislocation or loose body), but instead pseudo-instability or giving way of the quadriceps secondary to pain resulting in a sense of instability or catching. Candidates should be asked about the details of their instability or mechanical symptoms in order to separate instability from pseudo-instability. There is no pathognomonic knee examination finding in PFS, but the physical exam can reveal an abnormal Q-angle, generalized ligamentous laxity, hypo- or hyper-mobile patella, tenderness of the lateral patellar retinaculum, patellar tilt or mediolateral displacement, decreased iliotibial band flexibility, and external rotator muscle weakness (Fredericson & Yoon, 2006).

Over 40% of patients with PFS demonstrate abnormal patellar tracking (Draper et al., 2009). This can be related to structural features such as patellar tilt, patella alta, trochlear dysplasia, and increased Q-angle, or altered lower extremity biomechanics, associated with weakness of the hip and core muscles (Juhn, 1999; Souza et al., 2010). Testing involves having the candidate perform a single leg squat and observing for internal rotation of the knee and unsteadiness. Abnormalities at the foot, such as pes planus (flat feet) overpronation or pes cavus (high arch) oversupination may also be associated with PFS (Figure VIII-6). Foot position and PFS-related knee pain may improve with use of over-the-counter orthotics. Custom orthotics are only needed for individuals with severe foot deformity.

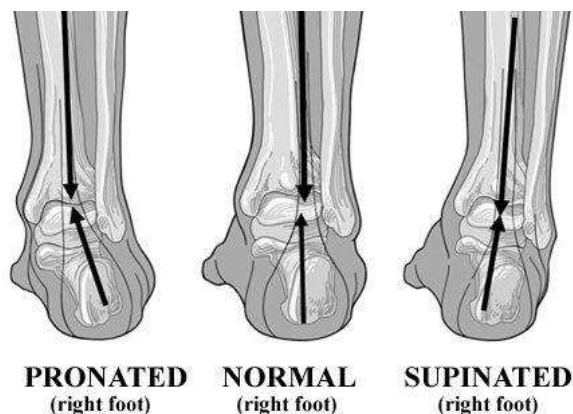


Figure VIII-6. Angulation of the Foot (viewed from the right heel)

Imaging: In cases of chronic PFS, radiographs of the knee may help evaluate patellar tilt and rule out other causes of pain. MRI is generally not needed or useful in the diagnosis or treatment of PFS.

Treatment: Treatment of PFS is non-surgical in the majority of cases. Generalized rest and a supportive knee sleeve or stabilizing brace help most, although there is a subset of individuals who will continue to have chronic symptoms (Collins et al., 2013; Nimon et al., 1998). Blond and Hansen

(1998) found that only 14% of female and 40% of male athletes with PFS remained pain free five years following non-operative treatment. Contributing factors, in particular notable weakness in the hip and core musculature, will benefit from focused strengthening. Rehabilitation should be pursued with care, as vigorous strengthening can result in increased pain. Careful technique during exercise and properly timed progression over weeks is critical to allow muscle building while avoiding pain. Straight leg raises and VMO strengthening may also be helpful, but resisted knee extensions should be avoided, as they result in high loads across the patella. Taping of the patella (e.g., McConnell Taping) to realign the patella may result in temporary symptom improvement. Major shifts in patellar alignment are not seen with taping, but are known to temporarily increase patellofemoral contact area, improve the tolerance to knee joint loading, and facilitate VMO activation in relation to the vastus lateralis (Derasari et al., 2010).

Patellar Chondromalacia and Arthritis

Chondromalacia (cartilage softening and disease) and osteoarthritis (cartilage loss) of the patella refer to cartilage abnormalities in the patellofemoral joint. The most common symptoms are pain under the patella, swelling, and mechanical symptoms (unlike in PFS). Reduced patellar mobility and crepitus may be noted during examination. In severe cases, osteophytes or bone spurs may be directly palpated.

Imaging: Initial radiographs alone are generally sufficient to make the diagnosis of patellofemoral arthritis. Malalignment may be noted on the merchant view. Weight-bearing films may also be useful. Arthritis will show joint space narrowing. An MRI is generally not indicated as radiographs are often sufficient for diagnosis. An MRI does detail cartilage loss more specifically; however, the degree of chondral loss is not well correlated with the degree of symptoms. In cases where MRI and clinical correlation is unclear, a bone scan can help determine if a chondral injury is metabolically active and a potential source of pain.

Treatment: Treatment of patellofemoral arthritis depends upon the degree of cartilage loss and the severity of symptoms. Most individuals will benefit from hip, quad, and hamstring strengthening while avoiding patellar overload. Some will benefit from a supportive brace, such as a knee sleeve or patellar cut-out (stabilizing) brace. If symptoms persist, corticosteroid or hyaluronic acid injections may be warranted.

b. Recommended Evaluation Protocol:

Candidates with a history of anterior knee pain, patellar subluxation, or patellar dislocation should be questioned regarding the frequency and recency of these symptoms, particularly instances of swelling, giving way, falling, sensations of instability, "gelling" (the perception of joint stiffness, usually lasting less than 20 minutes), or irritability of the knee after prolonged sitting. The [Kujala Anterior Knee Pain Scale](#) is a short, validated patient survey that quantifies and tracks the burden of such symptoms (Wang et al., 2010).

All medical records should be obtained and reviewed when significant history of prior treatment, dislocation, or surgery is present.

Candidates who meet all of the following criteria do not warrant further evaluation or work restrictions:

History:

- Participation at an activity level equivalent to the rigors of academy training for at least six months with no more than occasional mild pain that does not affect performance, and has not warranted treatment, doctor visits, or use of braces. Any sensation of instability requires further evaluation
- No subluxation or dislocation for the past two years if conservatively treated, or none for the past year if a realignment procedure was performed

- No history of observed Grade IV chondromalacia

Examination:

- Normal bulk and firmness of Vastus Medialis Oblique (VMO)
- Normal quadriceps size and function
- No effusion; normal range of motion
- Thigh Circumference Measurement: Prior knee injury is a risk factor for ongoing symptoms related to incomplete rehabilitation. This is suspected when there is significant muscle atrophy in the quadriceps or hamstrings. Isokinetic strength testing of the injured limb should be greater than 80-90% of the uninjured limb before there is a return to unrestricted physical activity. A side-to-side difference in thigh circumference should be no greater than 1 cm before returning to unlimited physical activity (Barber-Westin & Noyes, 2011a). Thigh circumference can be measured either at its maximal girth or at a standardized distance from the joint line (e.g. 15 cm), with the leg at rest (Jarvela et al., 2002). Candidates with significant atrophy (i.e. a side-to-side difference >20% in strength, or >1 cm in circumference) may benefit from further rehab prior to appointment or beginning the academy.
- Hop Test: Standing on one limb, the candidate hops as far as possible, landing on the same limb. The distance is measured and recorded. Each limb is tested 2-3 times, alternating between limbs. A result of greater than 90% of the distance hopped compared with the opposite (normal) side is acceptable (Barber-Westin & Noyes, 2011a).
- No tenderness with palpation of the peripatellar soft tissues.
- Patella smoothly exits from the femoral sulcus at 10-20 degrees of flexion and then moves no more than slightly laterally in the last few degrees of extension. There is no abruptness of patellar movement (J-sign).
- Normal hip and core strength: Using a single leg squat, there should be symmetry from side to side. Note any unsteadiness or internal rotation at the femur and increased valgus at the knee during the squat, indicating weakness. If noted, this strength deficit may be corrected via home exercise program or referral to a physical therapist.
- Normal foot pronation: This is particularly important when PFS is suspected (see Figure VIII-6). Individuals with excessive pronation or supination may benefit from a trial of over-the-counter orthotics and, if needed, podiatric referral for consideration of custom orthotics.

NOTE: Since the patellar apprehension sign may stay positive for many years following an episode of instability, it is not a useful indicator of current propensity to dislocate. However, it can serve as a general screening tool for those who deny a history of patellar instability (Figure VIII-7).

Radiographs:

- Tilt angle is open laterally
- Congruence angle at 45 degrees is on average -8 (range: -20 to +7 degrees)
- Presence of arthrosis is limited to mild degrees of subchondral sclerosis without notable joint space narrowing or spurring/ osteophytes



Figure VIII-7. Patellar Apprehension

From Hoppenfeld, Stanley, *Physical Examination of the Spine and Extremities*, 1st, ©1976. Electronically reproduced by permission of Pearson Education, Inc., New York, New York.

Candidates who have normal mechanics by kinematic patellar CT or MRI (TT-TG measurement) can be cleared. In deciding whether to restrict or defer, greater weight should be given to history, current activity level, and lower extremity function rather than radiographic abnormalities, as some individuals may display high function despite these abnormalities.

Evaluation Guidelines:

- Current or recent evidence of subluxation/dislocation substantially increases the risk of sudden incapacitation during a critical incident, due to falling or cessation of activity resulting from pain or instability. These candidates cannot perform full field duties.
- Patellofemoral pain (with or without tilt) without subluxation may increase the risk of pain with flexed knee activities, such as downhill running, stair climbing, jumping and landing, and squats. However, this may not be severe enough to impede an officer during a critical incident. Although it may lead to chondromalacia and arthrosis in some, this process takes much longer than two years to develop.
- Grade IV chondromalacia/moderate-to-severe arthrosis increases the risk of pain during running, stair climbing, squatting and lifting. Pain and "gelling" may occur after prolonged sitting. Although it may not rise to a level severe enough to impede an officer during a critical incident, there is a high likelihood of reflex giving way due to pain. If there is no history of giving way or limitations in running, cutting, and stair climbing, no restrictions are warranted for candidates who are active and otherwise acceptable.

- VMO or quadriceps atrophy: Refer to a physical therapist for further assessment and possible rehabilitation (with the possible exception of candidates with an exceptional athletic history). As explained above, muscle weakness increases the risk of patellofemoral pain.

9) Anterior Cruciate Ligament Instability

a. General Considerations:

The anterior cruciate ligament (ACL) is the most important ligament to knee function. Its primary role is to prevent excessive anterior subluxation and rotation of the tibia during high-stress activities such as pivoting, cutting, and jumping. Without the stabilization of the ACL, the knee is at significantly increased risk of giving way (GW) which could result in sudden incapacitation. The ACL is also important for a wide range of other relevant activities, such as walking on uneven ground and squatting (Tables VIII-2 and VIII-3).

Table VIII-2. Specific Task Performance (Percentage) in ACL-Disrupted Patients, 5 Years Since Injury*

Task	No Problem	Mild Impairment	Moderate Impairment	Unable to Do
Getting out of chair	100	0	0	0
Prolonged sitting	76	21	3	0
Walking	94	6	0	0
Walking on uneven ground	65	35	0	0
Ascending stairs	85	15	0	0
Descending stairs	88	12	0	0
Climbing	71	26	0	0
Kneeling or squatting	56	44	0	0
Jogging	71	23	0	6
Running fast	63	19	6	12
Jumping	66	22	3	9
Twisting or pivoting	53	35	3	9
Cutting	50	29	3	18

*Study performed at San Diego Kaiser; N=34. From Hirshman, H.P. et al., 1990. The fate of unoperated knee ligament injuries. Chap. 27 in Knee Ligaments: Structure, Function, Injury and Repair. eds. D.M. Daniel et al. Reprinted by permission of the publisher.

Table VIII-3. Pain, Swelling, and Giving Way in Chronic ACL Patients During Activities of Daily Living

Author	Number of Patients	Pain—More Than Mild or Infrequent	Swelling—More than Infrequent	Giving Way	Years of Average Follow-Up	Remarks
McDaniel, 1980	49	38%	10%	Not reported for ACL	14	
Noyes, 1983	103	30%	14%	21%	5.5	Selected population of “worst cases”
Hawkins, 1986	40	18%	18%	11%	4	30% who underwent reconstruction not included
Hirshman, 1990	34	0%	0%	9%	5	

From Hirshman, H.P. et al., 1990. The fate of unoperated knee ligament injuries. Chap. 27 in *Knee Ligaments: Structure, Function, Injury and Repair*, eds. D.M. Daniel et al. Reprinted by permission of the publisher.

Few individuals are able to return to full, nonsymptomatic athletic activity after an ACL tear that is non-operatively treated without significant limitations, particularly if full activity involves cutting/pivoting activities (Ramski et al., 2014). Recurrent GW and injury are very common in individuals with ACL insufficiency.

Strategies for treating ACL tears include: 1) non-surgical care, 2) delayed reconstruction, and 3) acute reconstruction. ACL reconstruction restores knee stability. Return to sports and high-level activities after ACL reconstruction has been reported at 70-90% (Arderm et al., 2011). However, some individuals may have residual instability or laxity of the knee following reconstruction. Incomplete rehabilitation may also result in a residual lack of strength or incomplete range of motion. Finally, meniscal tears are common at the time of or following ACL tear. Further injury to the meniscus is reduced following ACL reconstruction (Kessler et al., 2008).

Although candidates typically deny any current symptoms or functional problems and claim to be athletic, some remain at substantially increased risk of a GW episode or may have significant functional impairments. The challenge is to objectively make this determination on an individualized basis. That evaluation should consist of 3 parts: 1) history (primarily of instability, giving way, pain, and swelling), 2) testing for instability and weakness, and 3) functional testing, when indicated.

1. **History** should include questions regarding any prior injury to the ACL or other ligaments in the knee. An ACL deficient knee will typically result in giving way episodes during rapid changes in direction or speed. These episodes usually cause pain and swelling of limited duration. Between episodes, the knee is usually not swollen nor painful. A careful assessment of the candidate's current/recent activity level may help to identify individuals who are not functioning well due to ACL deficiency.

The [Lysholm Knee Score](#) is an eight-question patient survey that can be used to specifically quantify and track the burden of ACL symptoms (Wang et al., 2010). The Lysholm is frequently administered with another brief survey, the [Tegner Activity Score](#), which asks an individual to circle their highest pre-knee injury and current levels of activity from a standardized selection of choices (Briggs et al., 2009).

2. **Physical Exam Testing for Instability.** Because it is one of the primary stabilizers of the knee, ACL tears commonly result in instability or giving way, particularly with pivoting or rapid acceleration/deceleration. The following tests are effective in determining ACL deficiency. In all these tests, it is important to compare with the contralateral, uninjured side to evaluate baseline levels of laxity, which can vary significantly from one individual to another:

- a) **Lachman Test** (Figure VIII-8) has the highest overall sensitivity and specificity. With the extremity in slight external rotation and the knee held in 15-20 degrees of flexion, the femur is stabilized with one hand and firm pressure is applied to the posterior aspect of the proximal tibia, lifting it forward in an attempt to translate it anteriorly. Excessive anterior excursion as compared to the opposite knee, or a lack of firm end point are indicative of a positive test.

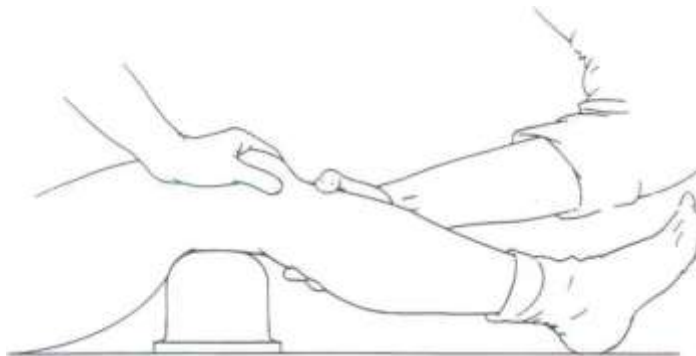


Figure VIII-8. The Lachman Test

From Dale, Daniel, M.D. Reproduced with permission from the author.

ACL grading incorporates degree of anterior translation and presence/absence of an endpoint.

Grade 1	0-5 mm
Grade 2	6-10 mm
Grade 3	>10 mm
<hr/>	
A	Endpoint present
B	Endpoint absent

After an acute ACL tear, an individual will typically have a grade 2B Lachman exam (anterior translation increased 6-10mm without a solid endpoint).

- b) **Anterior Drawer** is a classic test for ACL insufficiency. With the knee at 90° of flexion, the anterior translation measured. Similar to the Lachman, it is graded in 5 mm increments. Unfortunately, it only has a sensitivity of 33-54% (Donaldson et al., 1985; Jonsson et al., 1982). If results are equivocal, the Lachman test should take precedence.
- c) **Pivot Shift Test** is considered the most specific for instability and subsequent GW, as it can demonstrate rotatory instability in addition to anterior instability (Figure VIII-9). It is graded on a three- point scale: I = mild slipping or pivot glide, II = moderate slipping, and III = clunking, locking or dislocation. The Pivot Shift test is limited by poor sensitivity as compared to the Lachman (Hawkins et al., 1986; Donaldson et al., 1985). Furthermore, it is difficult to perform, even for experienced orthopedic surgeons (Noyes et al., 1991), and requires a relaxed patient to obtain an accurate result.

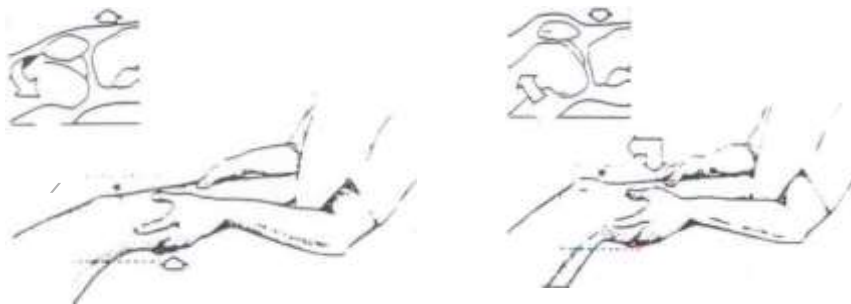


Figure A

Figure B

Figure VIII-9. Flexion-Rotation Drawer Test (A Method of Demonstrating a Pivot Shift)

- A. Flexion-rotation drawer test, subluxated position. With the leg held in neutral rotation, the weight of the thigh causes the femur to drop posteriorly and rotate externally, producing anterior subluxation of the tibia.
- B. Flexion-rotation drawer test, reduced position. Gentle flexion and a downward push on the leg reduces the subluxation.

The test is graded: 0 = no shift, 1+ = slight shift, 2+ = moderate shift, and 3+ = momentary locking.

From Noyes, F.R., et al 1980. Arthroscopy in acute traumatic hemarthrosis of the knee. *J Bone Joint Surg Am.* 62A(5):687-095,757. Reprinted by permission of the publisher (<http://jbjs.org/>).

– Physical Exam Testing for Weakness

Many individuals have incomplete recovery after ACL injury and surgery, resulting in chronic weakness. The quad and hamstring are most often affected. The hamstring is an important stabilizer of the ACL as it exerts a posterior force on the tibia when contracted. However, the quadriceps are equally important for stabilizing the knee, especially during functional activities.

Weakness is first evaluated by visual inspection of the leg for atrophy or muscle loss. A measurement of thigh circumference is a more objective measure of muscle loss.

Hopping tests are useful lower-limb functional tests, requiring a minimum of space, equipment, and time (Rohman et al., 2015; Hegedus et al., 2015):

i) *Single hop for distance* – Standing on one limb, the candidate hops as far as possible, landing on the same limb. The distance is measured and recorded. Each limb is tested 2-3 times, alternating between limbs.

ii) *One-legged timed hop* - A distance of six meters is measured. The candidate is encouraged to use large forceful one-leg hopping motions, performing a series of hops over the total distance. A series of two tests are completed for each limb; mean times are calculated to the nearest one-hundredth of a second.

The single-leg squat, retro step-up and crossover triple hop are also highly useful functional tests.

Expected absolute values are a function of gender and level of sports participation. Symmetry is unaffected by these factors (Barber et. al, 1990). Normal symmetry is always $\geq 80\%$ and usually at least 85% (Table VIII-4). Daniel, Stone & Riehl (1990) found that 95% of normals had a symmetry score of 90% in the single hop test.

Table VIII-4. Limb Symmetry in One-Legged Hop Testing of Normal Patients

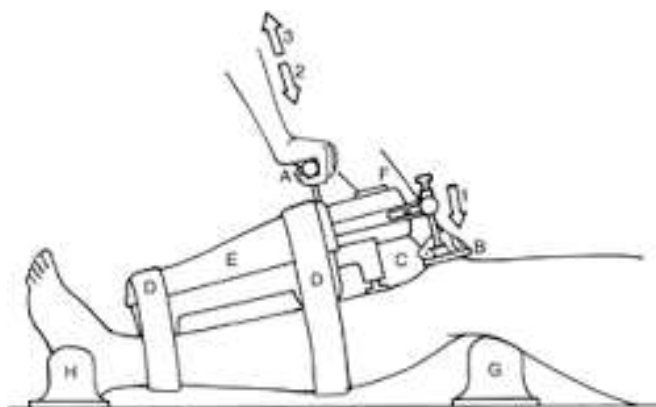
Limb symmetry index	Percent of normal patients	
	Hop for distance	Timed hop
.90	81%	71%
.85	93%	92%
.80	100%	100%

Reproduced with permission from Barber, S.D. et al., 1990. Quantitative assessment of functional limitations in normal and anterior cruciate ligament-deficient knees. *ClinOrthopRel Res.* 205:204-214.

3. **Additional Functional Testing for Stability and Strength.** Physical exam testing for ACL injury is highly accurate when performed correctly by an experienced practitioner. Arthrometer testing to measure ACL laxity (anterior tibial translation) can be useful for research purposes, but it may not be more effective diagnostically than traditional physical examination when used clinically (Pugh et al., 2009).

Arthrometer:

The KT-1000 and KT-2000 (MEDmetric, San Diego) are the mainstays of knee-laxity testing devices (Figure VIII-10). The maximum manual force test has ~90% sensitivity and ~95% specificity in diagnosing ACL insufficiency (Pugh et al., 2009). Figure VIII-11 illustrates the expected results in normal vs. ACL-deficient knees (Daniel, 1990). One drawback of the arthrometer is that it measures anterior tibial translation, but not rotational stability. Both favorable and unfavorable results have been reported, generating controversy about the device's reliability.



The limbs are supported with a thigh and foot rest (G,H). The arthrometer is placed on the anterior aspect of the leg and held with velcro straps (D). Two sensor pads: one in contact with the patella (B) and the other in contact with the tibial tubercle (C) move freely in the anterior-posterior plane in relation to the arthrometer case (E). The instrument detects the relative motion in millimeters between the two sensor pads and, therefore, motion of the arthrometer case does not affect the measurement which is displayed on the dial (F). Displacement loads are applied through a force sensing handle (A). A tone indicates when a 15 and 20 lb. displacement force is applied. With adequate stabilization of the patella in the femoral trochlea, tibial tubercle motion relative to the patella accurately reflects the motion of the tibia relative to the femur.

Figure VIII-10. KT-1000 Test

Reproduced with permission from Daniel, D.M., and Stone, M.L. 1990. KT-1000 anterior-posterior displacement measurements. Chap. 24 in Knee Ligaments: Structure, Function, Injury, and Repair. eds. D.M. Daniel et al. New York: Raven

Isokinetic machines such as the "Cybex" or "Biodex":

From a sitting position, the individual extends and flexes the knee as forcefully as possible, while a mechanical arm attached to the ankle maintains constant angular speed. Numerous parameters, such as angular velocity, number of repetitions, peak torque, maximum and average work are measured. There is no consensus as to which parameter is functionally relevant, and no isokinetic protocols have been validated as a useful predictor of successful return to sports activities (Undheim et al., 2015).

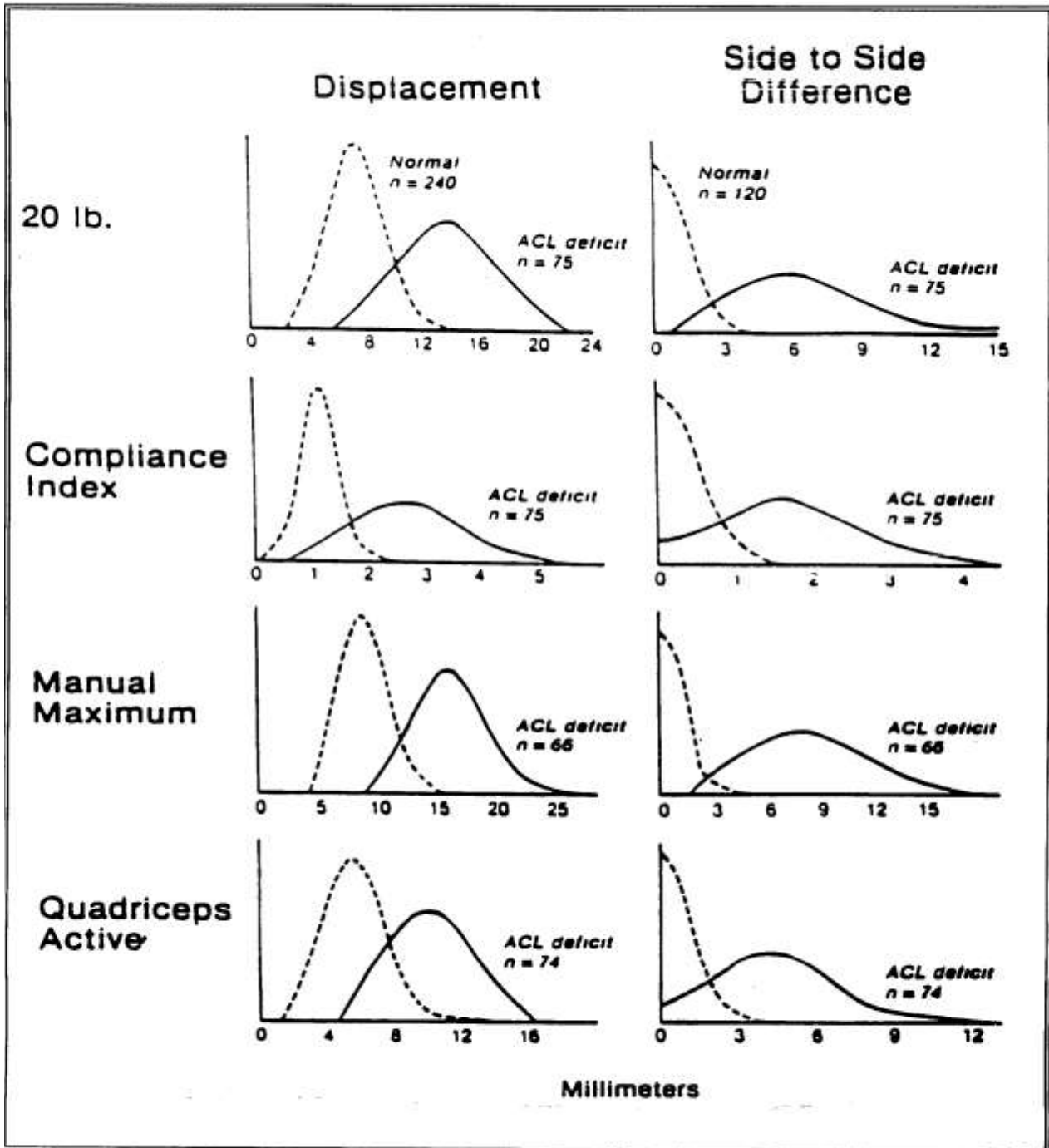


Figure VIII-11. KT-1000 Measurements

Anterior Displacement Measurements for 120 Normal Subjects (240 knees) and for a Group of Patients with a Chronic ACL Disruption. Frequency distribution: 30° of Knee Flexion.

Reproduced with permission from Daniel, D.M. and Stone, M.L. 1990. Knee Ligaments: Structure, Function, Injury and Repair. Figure 24-8, New York: Raven Press.

Partial ACL Tears: The ACL ligament is composed of two major fiber bundles (antero-medial and postero-lateral) contained within a synovial sheath. The large majority of ACL tears are complete, but 5-15% involve a partial tear involving only one of these fiber groups (Pujol et al., 2012). This injury will have a history similar to that of a complete ACL tear: tearing sensation or pop after a pivoting or jumping injury with subsequent pain, swelling, difficulty bearing weight, and the sensation of instability (DeFranco & Bach, 2009). Although many with a partial tear do well with conservative care and activity modifications, there is a substantial risk of progression to complete tear (Table VIII-5). This risk is directly proportional to the amount of the tear: 86% of 3/4 tears and 50% of 1/2 tears progressed to full tears at follow-up 24-110 months later (Noyes et al., 1989). One-quarter tears were much less likely to progress. Other risk factors for progression are initial AP laxity and subsequent reinjury. In the group of 32 patients studied, 56% were reinjured within two years after the initial injury. This is consistent with the observation that a substantial number of partial tears progress to complete tears, with the majority of such individuals unable to return to their preinjury activity level (DeFranco & Bach, 2009).

Table VIII-5. Partial ACL Tears

Clinical Significance	
Buckley, 1989	40% fair-poor results 56% did not engage in pre-injury sports (N=25; follow-up = 4 years)
Kannus, 1987	33% did not engage in pre-injury sports 7% had to change occupations due to knee 15% had three or more reinjuries 68% had anterolateral instability on exam (N=41: follow-up = 8 years)
Odensten, 1985	All had at least good results (N=21; follow-up = 6 years)
Risk of Progression to Full Tear	
Sandberg & Balkfors, 1987	62% of 29 patients initially stable during anesthesia exam found to have instability 12-60 months later
Finsterbush, 1990	26% of 42 patients progressed to full tear within 4 years
Odensten, 1985	14% of 21 patients stable at 21 months developed instability by 70 months
Noyes, 1989 (c)	38% of 32 patients progressed to full tear at 24-110 months follow-up

Derotational Braces are sometimes prescribed for a period of time after surgery (Nyland et al., 1998). Bracing has been shown to decrease but not eliminate the risk of GW. For example, Bonamo et al. (1990) found that bracing reduced the prevalence of GW from 47% to 23% during sports participation in patients with unrepaired, complete ACL tears.

There is no conclusive information demonstrating that bracing improves real-world function and performance or decreases the rate of injury in an ACL-deficient knee (Tegner & Lysholm, 1985; Rishiraj et al., 2009; DeFranco & Bach, 2009). Moreover, braces tend to migrate during real-world use, which hinders performance. Bracing may also decrease running speed and agility while increasing energy expenditure and fatigue. Braces may become uncomfortable after prolonged sitting or driving. They also must be worn on top of the uniform, making it questionable that it would be worn at all times while on duty. Therefore, use of a brace is not a viable option for peace officers.

b. Recommended Evaluation Protocol:

Candidates with a history of ACL injury should be questioned regarding symptoms of pain, swelling, and instability. Those with partial tears should be asked specifically about giving way. Details regarding surgery, physical therapy, and use of braces must be investigated. Pre-injury and post-injury sports participation should also be determined, and in particular, why the candidate did not return to pre-injury status if that is the case.

Medical record review should include all imaging and operative reports.

Physical examination of both knees should include the following (in addition to that outlined in Section II.A.):

- Lachman test
- Anterior drawer
- Pivot shift test (most commonly performed by an orthopedist, as it is difficult to perform in some individuals due to guarding)
- Range of motion (should not have a flexion deformity of 10 degrees or limitation of flexion to < 120 degrees)
- Strength and functional testing (e.g. hop test)

Radiographs consisting of a lateral, standing AP, and a 45 degree patellar view (Merchant) should be obtained when a history of ACL injury is ascertained. Radiographs will detail the presence of implants within the knee and may show signs of early osteoarthritis, such as bone spurring or joint space narrowing.

Ancillary testing such as arthrometer or isokinetic muscle testing can provide documentation. Although not usually necessary, it can be helpful for those candidates who are unable to return to full activity or in those with partial tears who exhibit subtle symptoms of instability.

Any of the following is evidence that a candidate is at a substantially increased risk of a sudden incapacitation and/or may have significant functional impairments, regardless of a denial of problems:

- Instability: 2+ Lachman, 2+ Anterior drawer, or Pivot shift positive
 - History of recurrent GW episodes
 - >5 mm side-to-side difference on 20 lb. KT-1000 test
 - >7.5 mm Side-to-side difference on maximum manual KT-1000
- Weakness: Hop test, quadriceps, or hamstring asymmetry >15%
- Poor activity history: Less than a 1-2 year recent history of successful participation in high-activity level sports
- Recent tear or repair:

ACL Reconstruction is reported to produce normal or near-normal knee results in >90% of individuals. Objective criteria for a full return to sport after surgery include full knee motion, an absence of a joint effusion, thigh muscle strength of 80-90% in the contralateral joint, thigh circumference within one cm. of the contralateral side, and single-leg hop test with >90% distance of the unoperated leg (Barber-Westin & Noyes, 2011b). The rate and timing of a return to sport activities depends on several factors, including the presence of concomitant injuries in the knee, the surgical graft type, age, particular sport, level of competitive play, and psychological factors (Bauer et al., 2014).

Abnormal joint kinematics are seen at three months post-operatively for walking, 5-12 months in downhill running, and 4-12 months in single-leg hopping. Complete graft healing and ligamentization can require 10-12 months (AAOS, 2012a). The American Academy of Orthopaedic Surgeons suggests 6-12 months before a return to sports and physically demanding activities after surgery (AAOS, 2012b). Generally, no strenuous activity, except for physical therapy, is advised during the first 12 weeks post-operatively. In a systematic review of clinical studies 40% permitted running at three months, 45% permitted cutting/pivoting sports at six months, and 50% permitted return to sport without restrictions at six months post-operatively (Harris, Abrams, & Bach et al., 2014). Nevertheless, after surgical reconstruction, only 30% of recreational athletes return to their pre-injury level of sports activity at one year and 60% of athletes at two years due to demographic, physical function and psychological factors (Ardern et al., 2015; Ardern et al., 2013). Therefore, candidates who have undergone ACL reconstruction should be prohibited from running, cutting, and jumping for one year after surgery.

History of Partial Tear: Partial ACL tears appear functionally equivalent to complete tears and only 18% of individuals with a partial ACL tear return to their pre-injury level of activity (Pujol et al., 2012; DeFranco & Bach, 2009). Given the physical demands of the job demands, candidates with a partial ACL tear should be considered a high risk for progression to ACL deficiency (DeFranco & Bach, 2009). However, those with a successfully rehabilitated partial ACL tear can anticipate a

return to full activity in approximately three months; candidates should be restricted from critical incidents requiring running, cutting, and jumping during this time.

Full Tear, Unrepaired, or Return ACL Reconstruction. Full tear, unrepaired candidates should be evaluated using the protocol described earlier. They should initially be restricted from running, cutting, and jumping. Given the poor prognosis associated with test results indicating instability (i.e. grade >2 Lachman, pivot shift test positive) (Ramski et al., 2014), indefinite deferral should be considered until further recommendations from an orthopedic surgeon regarding the need for ACL reconstruction and the likelihood of a full return to activities. Even candidates with a stable joint examination should be considered for further examination under anesthesia and diagnostic arthroscopy with the possibility of surgical treatment (DeFranco & Bach, 2009). The outcomes after a second knee injury and surgery are significantly less favorable than outcomes after a primary injury (Hewett et al., 2013).

10) Collateral Ligament Instability

Isolated complete tears of the medial collateral ligament (MCL) do not require surgery and have a generally benign prognosis, even in injured football players (Jones et al., 1986; Indelicato et al., 1990). However, the prognosis is poor when there is concomitant anterior cruciate laxity. One follow-up study of 27 patients found that most had symptoms and muscle weakness (Kannus, 1988).

Those with a history of MCL tears should be examined for AP laxity and thigh atrophy. If the candidate is asymptomatic and has no cruciate laxity or significant thigh atrophy (>1/2"), no restrictions are necessary, even if mild residual MCL laxity to valgus stress is present. In these cases, radiographs and record review is not necessary.

The evaluation of candidates with tears of the lateral collateral ligament (LCL) is similar to that of MCL deficient candidates. This injury is quite uncommon. The few studies that exist indicate that the prognosis for partial tears (Grade II) is quite good (Kannus, 1989; Ellsasser et al., 1974). However, complete tears (Grade III) are usually associated with cruciate damage, or involvement of the posterolateral corner (PLC) of the knee with injury to the LCL, popliteus tendon and popliteofibular ligament. In these cases, the prognosis is particularly poor without surgery (Kannus, 1989).

For PLC injuries, a prompt diagnosis is very important, as surgery within 2-3 weeks of the initial injury maximizes the chance for a successful outcome. Examinations to diagnose a PLC injury include the dial test and varus stress test (LaPrade & Wentorf, 2002):

- **Dial test.** The individual lies prone with the legs adducted together with knees flexed at 30° and ankles dorsiflexed. The lower legs are “dialed” in external rotation and compared to the motion of the tibial tubercle. External rotation of the tibial tubercle in the affected knee is compared to the healthy knee. A difference > 10-15° indicates an injury to the posterolateral knee. The test is repeated with

knees flexed at 90°. Increased tibial tubercle rotation indicates a combined PCL and PLC knee injury. Decreased rotation indicates an isolated PLC injury.

- **Varus stress test** at 0° and 30° is best performed with the individual lying supine. Standing next to the candidate just laterally to the knee, the knee is grasped by the examiner, with fingers directly over the knee joint line, and the distal shin/ankle is supported on the examiner's waist by the examiner's elbow. A slight traction is placed on the distal leg and a varus opening stress is applied to the knee with the knee fully extended at 0° flexion and again at 30° flexion. A gap opening with the knee fully extended indicates a serious posterolateral injury with cruciate ligament involvement. Greater than 5 mm. of joint opening with the test at 30°, especially if asymmetric compared to the normal knee, suggests tearing of the fibulocolateral and lateral capsular ligaments and damage to other posterolateral structures.

11) Shin Splints [Medial Tibial Stress Syndrome (MTSS)]

a. General Considerations

Shin splints (MTSS) refers to pain in the front of the shin or tibia. It usually arises insidiously after a history of increasing running activity. Differentiating shin splints from stress fracture or stress reaction can be difficult. The periosteum of the medial tibia are the cause of MTSS, whereas stress reaction or fracture involves the tibia bone itself. MTSS will often resolve with rest, a stretching program, and when indicated, orthotics may be useful.

Evaluation. Individuals with MTSS often present with diffuse tenderness over the medial aspect of the tibia. Pain and tenderness is more common in the mid-to-distal posteromedial tibia, and slight swelling may be present. Pain in the calf or lateral ankle is usually not present. Associated findings include an increased range of motion in ankle plantar flexion and hip external rotation, increased navicular drop (which is related to a lower arch height and increased tibial internal rotation), and an elevated body mass index (Hamstra-Wright et al., 2015). Foot alignment while standing and gait should be evaluated for flat feet/pes planus (causing overpronation) or high arches/pes cavus (causing underpronation).

Imaging is generally not necessary for initial assessment and diagnosis. An MRI may be necessary if there is concern regarding stress reaction or fracture of the tibia. Stress fracture risk factors include a history of prior stress fracture, a sudden increase in activity, and focal point tenderness over the shaft of the tibia (as opposed to a broad area of pain along the periosteum with MTSS).

Treatment. MTSS is generally managed using rest, ice, a compression sleeve, physical therapy, calf stretching and other non-surgical approaches; however, no approach has proven superior to others (Reshef & Guelich, 2012; Winters et al., 2013; Moen et al., 2012). A careful analysis of activity level and shoe wear is often helpful. A more supportive shoe, over-the-counter orthotics, or referral to podiatry for custom orthotics may be considered if rest and stretching do not result in improvement, or if alignment abnormalities are present. MTSS will rarely require

extensive time off work, but can be a chronic irritation that limits running and sprinting in susceptible individuals. Shock-absorbing and biomechanic shoe orthosis may be helpful in the prevention of MTSS (Larsen et al., 2002; Khan et al., 2013), but further research on this topic is forthcoming (Bonanno et al., 2015).

b. Recommended Evaluation Protocol

Candidates should be asked about current or previous shin pain. If present, tenderness in the medial tibia and foot position/alignment should be ascertained.

- A history of MTSS that responded to a stretching program or shoe alteration and no symptoms for more than six months: no further action is required.
- A recent onset of symptoms (<3 months) and normal foot position: a calf muscle stretching program should be initiated. A shock absorbing insole should be suggested.
- Current symptoms and inability to run >3-4 miles/day: recommend a calf stretching program and referral to podiatry and an MRI to exclude a stress fracture (Moen et al., 2009).
- Long-standing symptoms and an inability to run: disqualification. An evaluation for less common causes of exertional leg pain, including chronic exertional compartment syndrome or popliteal artery entrapment, can be considered.

12) Ankle Instability

a. General Considerations

Ankle instability refers to deficiency of the lateral supporting structures of the ankle, generally occurring after multiple ankle sprains. The ligaments that may be affected are the Anterior Talofibular Ligament (ATFL- most commonly injured), Calcaneofibular Ligament (CFL), and the Posterior Talofibular Ligament (PTFL) (Figure VIII-12). Chronic ankle instability causes frequent rolled ankles or sprains, resulting in sudden incapacitation.

Examination. Ankle instability may be categorized into acute and chronic. Acute instability is essentially an ankle sprain or rolled ankle. The ankle is typically inverted and supinated, resulting in increased stress on the lateral structures. In higher energy injuries, the ligaments may tear,

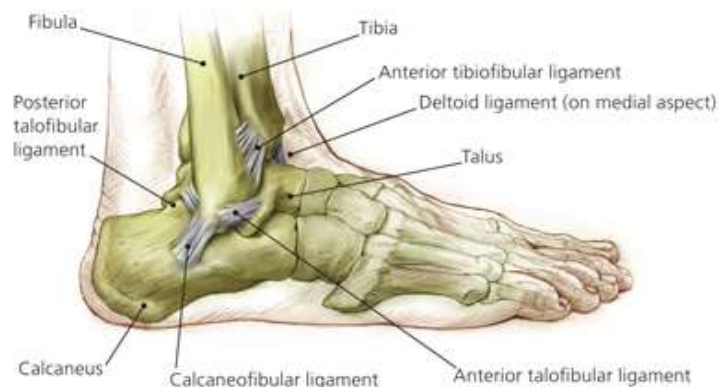

Figure VIII-12. Ankle Ligaments

resulting in significant swelling and an inability to bear weight. Most ankle sprains are low-grade (involving only the ATFL) and require a short period of rest, icing, compression, and elevation (RICE) prior to return to work. Severe swelling, inability to place weight on the leg, or bony tenderness on exam warrant placement on crutches and referral for radiographs to exclude fracture, based on the Ottawa Ankle Rules protocol (Stiell et. al., 1992).

Chronic ankle instability may be more difficult to diagnose. Candidates should be questioned regarding: 1) the number of sprains on each ankle, 2) current and recent ability to do high-level activities such as cutting sports, 3) brace wear, and 4) time to recovery after sprains. The focus of questioning should be on recent sprains, as a history of frequent sprains only during childhood or adolescence (which do not continue into adulthood) is not uncommon.

Individuals may have tenderness over the ATFL (anterior to the lateral malleolus) or the CFL (inferior aspect of the lateral malleolus). If there has not been a recent sprain, tenderness is often not present. Range of motion should be equivalent to the unaffected side. An anterior drawer test (Figure VIII-13) or inversion test (Figure VIII-14) may also detect instability. In the anterior drawer test, the heel is cupped by the examiner's hand while the other hand stabilizes the distal tibia. The foot is placed in neutral to slight plantar-flexion and forward pressure is applied to heel and anterior translation is noted. A side-to-side difference of 5mm. indicates instability and warrants referral to an orthopedic foot and ankle specialist.

In the inversion test, the ankle is inverted and pain or lateral opening is noted in the unstable ankle. Both sides are compared. Functional tests may detect not only instability but the weakness associated with chronic instability. These include 1) single leg stance time (standing on toes), 2) single leg hop, and 3) ability to do repeated single heel rises (usually 10). The affected side should be at least 85% of the normal side.

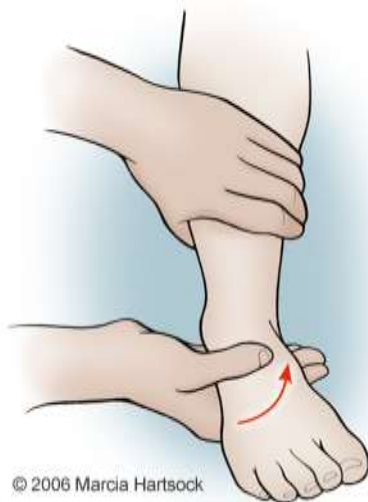

Figure VIII-13: Anterior Drawer Test of Ankle
Illustration © Marcia Hartssock

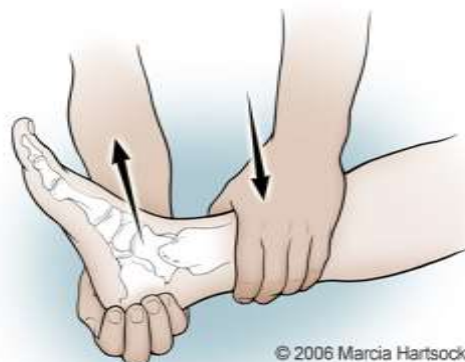

Figure VIII-14: Inversion Testing for Chronic Ankle Instability
Illustration © Marcia Hartssock

Imaging: Standing AP, lateral, and mortise radiographs of the ankle should be ordered in candidates with suspicion of current instability or multiple remote sprains, especially if severe. The radiographs should be examined for old avulsion fractures indicative of prior instability, irregularity of the ankle mortise, and evidence of osteoarthritis. MRI or stress radiographs can be useful to evaluate individuals with ongoing chronic instability, or who may benefit from surgical ligamentous reconstruction. Surgical intervention is rarely necessary.

Treatment: Most individuals will benefit from strengthening and proprioceptive balance exercises, which have been shown to decrease sprain recurrence in athletes. Ankle bracing also can be effective. A lace-up or Velcro ankle brace with a stiff stirrup that supports the medial and lateral ankle will often mitigate sprain risk. When well-fitting and used continuously, they can offset further injury and improve function in higher-level activities. Early referral to physical therapy for an exercise program and recommendation of an ankle brace is warranted upon the diagnosis of ankle instability. As noted above, if bracing and rehabilitation fail, some individuals may be candidates for surgical stabilization (Kerkhoffs et al., 2012).

b. Recommended Evaluation Protocol:

1) Single Acute Sprain: Individuals should be symptom-free and participating in high-level activities for a minimum of three months. The ankle exam should be normal.

2) Remote, Infrequent Sprains: Many active individuals may have a history of 1-2 ankle sprains. No further treatment is warranted if the sprains occurred >1 year ago and the physical exam is normal. If there is concern for mild instability, referral to an orthopedic foot and ankle specialist is warranted.

3) Multiple Prior Sprains: If weakness and instability signs are noted, the candidate cannot be cleared, given the high risk of ongoing instability. If only mild signs are detected, initial referral to an orthopedic foot and ankle specialist should be initiated.

13) Iliotibial Band Syndrome

a. General Considerations

Iliotibial Band (ITB) Syndrome is an extremely common finding in active individuals, especially runners and cyclists. The iliotibial band is a fascial structure composed of dense connective tissue that assists stance stability and is capable of resisting large varus torques at the knee. Proximally, the iliotibial band provides an insertion for the tensor fascia lata and gluteus maximus muscles. Distally, the iliotibial band inserts at Gerdy's tubercle on the lateral, proximal tibia.

ITB Syndrome is described as a friction syndrome which causes knee pain at the lateral femoral epicondyle distally. It can be associated with "hip" pain at the greater trochanter of the femur proximally, also referred to as "trochanteric bursitis." ITB syndrome is an overuse injury most commonly seen in runners with an imbalance of hip muscle strength, flexibility and lower limb kinematics. Pain is usually present during the offending activity only but may be present at rest in severe cases. The pain is commonly very sharp and "knife-like." Similar to MTSS, ITB Syndrome can

develop during training. It is important to exclude the lumbar spine as the etiology of leg pain by taking a careful history and performing a physical examination.

Candidates should demonstrate full mobility of the spine, hip and knee. Tenderness to palpation of the greater trochanter, lateral epicondyle, or along the entire ITB may be present. Swelling generally is not present. The Ober test (Figure VIII-15) is most commonly used to evaluate for ITB syndrome. The individual lies on the unaffected side. The leg is then abducted with the hip extended and the knee bent. In a normal test, the examiner allows the knee to slowly drop toward the unaffected side. No pain or stiffness is noted. When the ITB is tight, the leg will remain abducted and pain may result. Hip strength can be tested using either manual muscle testing with resisted hip abduction (easily performed after the Ober test) or a functional exam such as the single leg squat test. Individuals should also be evaluated for foot pes planus/excessive pronation and significant leg length discrepancy.

Imaging is generally not helpful in diagnosis or treatment of ITB Syndrome, except to exclude other diagnoses.

Treatment is focused on pain reduction and improving flexibility (Baker et al., 2011). Initial rest from running, ice, and anti-inflammatory medication will relieve initial pain and inflammation. In more severe cases, a local corticosteroid injection at the site of friction between the ITB and lateral femoral condyle can be considered. The focus during the subacute phase is on a stretching program and myofascial release with use of a foam roller and/or massage therapist. In the recovery strengthening phase, the focus is on gluteus medius and maximus function. There is limited evidence for the effectiveness of orthotics in treating ITB Syndrome. ITB Syndrome may frequently affect runners or candidates in training, but it is unlikely to cause sudden incapacitation (Strauss et al., 2011).

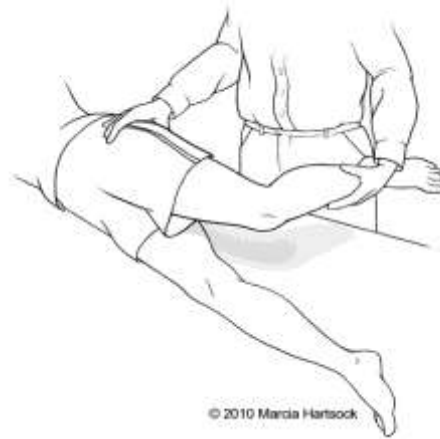

Figure VIII-15. Ober test

Illustration © Marcia Hartsock

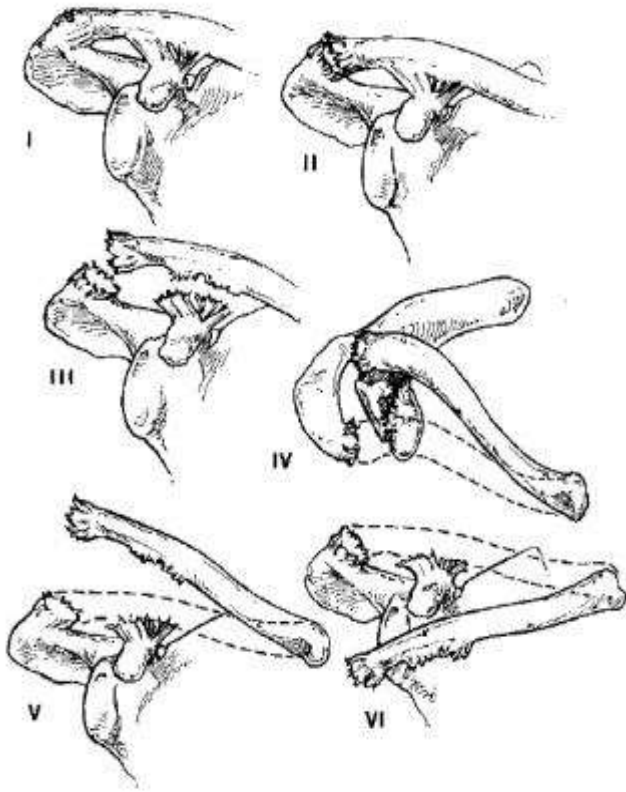
b. Recommended Evaluation Protocol

Candidates with a history of ITB Syndrome but no current symptoms and a normal exam should be cleared (Ferber et al., 2010). Candidates who develop symptoms during training should be referred to their personal physician for physical therapy consisting of manual treatment, stretching, and progression with closed-chain strengthening exercises (Baker et al., 2011). If symptoms continue after physical therapy, the candidate should be evaluated for other diagnoses (e.g. meniscal tear, stress reaction or fracture, or an abnormality of the hip or lumbar spine).

14) Acromioclavicular (AC) Joint Separation

An AC joint separation is an injury of the ligaments that hold the acromion and clavicle in place. An AC joint separation involves the ligaments that hold the

acromion and clavicle in place. These are sprained in grade I and ruptured in grade II AC joint separations. The coracoclavicular ligaments connect the clavicle (more medially) to the coracoid process of the anterior scapula. Type III, IV, V and VI acromioclavicular separations are characterized by disruptions of both the coracoclavicular and acromioclavicular ligaments. These ligaments are injured in more severe AC joint separations. The most commonly used classification system for AC joint separation is that of Rockwood (Figure VIII-16).



Type I: Minor sprain of the acromioclavicular ligament, intact joint capsule, intact coracoclavicular ligament, intact deltoid and trapezius

Type II: Rupture of the acromioclavicular ligament and joint capsule, sprain of the coracoclavicular ligament but intact coracoclavicular interspace, minimal detachment of the deltoid and trapezius

Type III: Rupture of the acromioclavicular ligament, joint capsule, and coracoclavicular ligament; elevated clavicle ($\leq 100\%$ displacement); detachment of the deltoid and trapezius

Type IV: Rupture of the acromioclavicular ligament, joint capsule, and coracoclavicular ligament; posteriorly displaced clavicle into the trapezius; detachment of the deltoid and trapezius

Type V: Rupture of the acromioclavicular ligament, joint capsule, and coracoclavicular ligament; elevated clavicle ($>100\%$ displacement); detachment of the deltoid and trapezius

Type VI (rare): Rupture of acromioclavicular ligament, joint capsule, and coracoclavicular ligament; the clavicle is displaced behind the tendons of the biceps and coracobrachialis

Figure VIII-16. Rockwood Classification of AC Joint Separation

Source: Rockwood CJ, Williams G, Young D. Disorders of the acromioclavicular joint. In: RockwoodCJ, MatsenFAIII , eds. The Shoulder. 2nd ed.Philadelphia: WB Saunders; 1998:483-553

Candidates with a history of Grade I or II separations in the last several months should be deferred until they are asymptomatic, non-tender, and have a normal range of motion with full strength for at least one month. A thorough history, examination, and record review should be conducted to identify the estimated 8% of Grade I and 13% of Grade II individuals who suffer persistent significant symptomatology (Cox, 1981). Surgical treatment is not needed for these injuries. Most individuals have minimal if any chronic deformity at the AC joint. Individuals with Grade I or II separations are at higher risk for development of AC joint arthritis as they age.

Candidates with a recent Grade III injury should be deferred for at least three months from the date of injury, and at least one month after the resumption of full activity, as the majority will do poorly and require surgery (Taft et al., 1987). At that

time, the candidates should be questioned regarding recent symptoms especially with lifting heavy loads, since an estimated 25% will have difficulty due to residual pain or a sense of instability (Dias et al., 1987). Those who experience pain, weakness, tenderness, or a significantly decreased range of motion should be deferred until evaluated by an orthopedist.

A remote history of AC joint separation requires a thorough history and examination. In general, evidence of persistent Grade III separation is not of concern if the candidate is asymptomatic, the examination is otherwise negative, and there is no history of pain lasting more than three months within the past year.

Those with Grade III AC separations who are treated nonoperatively generally do quite well. However, individuals with persistent symptoms after a Grade III AC separation should be deferred or referred to the orthopedist. Individuals with a Grade IV, V, or VI AC separation require urgent referral to the orthopedist, especially when acute or recent. Complications from AC joint injuries may include cosmetic deformity, accelerated osteoarthritis, distal clavicle osteolysis, and decreased shoulder range of motion and upper extremity strength.

Forty-five percent of individuals with a history of AC separations will have some evidence of radiographic degenerative disease, but these changes are generally poorly correlated with symptomatology². Many individuals presenting with shoulder pain, especially those >35 years old and those with a history of weight lifting, will also show radiographic evidence of degeneration at the AC joint. These changes are also poorly correlated with symptoms. Although radiographs are not helpful from a prognostic perspective, they may be useful in establishing a baseline for future compensation purposes. In certain cases, radiographs may also help distinguish between a history of AC separation and a shoulder dislocation.

15) Anterior Shoulder Subluxation and Dislocation

a. General Considerations:

The shoulder joint is a highly mobile structure whose stability depends on a complex interaction between static stabilizers, such as the glenoid labrum and the glenohumeral ligaments, and the dynamic forces of the surrounding musculature that compress the head of the humerus into the glenoid fossa. Clinically, instability is most commonly associated with a tear of the labrum. Subsequent subluxation and dislocation usually occurs anterior and inferior. In these instances, the joint is most unstable when the arm is stressed in an externally rotated and fully abducted overhead position (Figure VIII-17). Only anterior instability is discussed here.

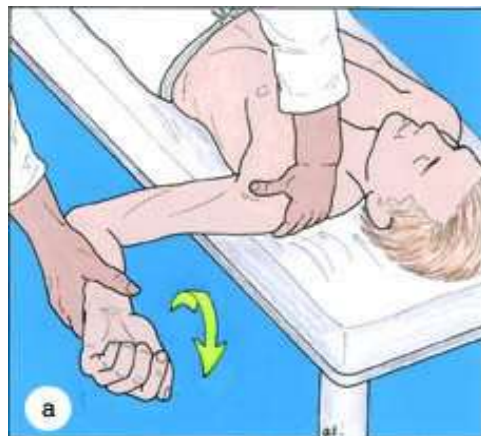

Figure VIII-17. Apprehension Sign for Shoulder Instability

From Steinfeld et al., A Commonsense Approach to Shoulder Problems Mayo Clinic Proceedings, August 1999, Vol 74, pages 785-794. Reprinted by permission of the publisher.

Individuals with mild anterior subluxation may report only mild pain (Warren, 1983). This is related to inflammation within the rotator cuff and capsule due to abnormal traction placed on these tissues. Those with more severe instability are aware of episodes of subtle movement of the shoulder in and out of the socket, and report that they do not "trust" the shoulder (Simonet & Cofield, 1984). Often these episodes are associated with a severe transient pain that shoots down the arm resulting in a "dead arm" sensation. The sensation will gradually clear after several minutes, but then be followed by feelings of weakness or pain (Warren, 1983).

Spontaneous relocation may or may not occur in anterior dislocations. If the shoulder remains dislocated, there will be further severe pain and inability to move the arm. A deformity with flattening of the shoulder contour may also be observed. The shoulder may fully dislocate and then revert back with minimal movement of the arm or self-manipulation. Individuals typically describe the shoulder as having popped out and then returning in place. Conversely, those with subluxation are more likely to describe shifting of the shoulder and concern that it may dislocate. Usually, no effort will be required for the shoulder to shift back into place. Those with a history of dislocation may also complain of symptoms consistent with intermittent subluxation.

Both subluxation and dislocation can cause sudden incapacitation, particularly during strenuous activities, such as wrestling combative arrestees or climbing walls.

SUBLUXATION: Typically, mild instability only causes pain during repetitive motion activities (such as weight training). The number of individuals who will progress to suffer the symptoms of more severe instability described above cannot be predicted. Those with only mild instability will generally be more responsive to physical therapy focusing on stabilization of the scapula and dynamic stabilizers. Most individuals will not progress to more severe instability unless further injury occurs.

The evaluation of relative instability involves detection of the following clinical signs (although they are not always present, even with a history of dislocation):

- **Apprehension Sign** (Figure VIII-17) checks for a possibly torn labrum or anterior instability problems. The arm of the relaxed, supine candidate should be abducted to 90° and progressively extended and externally rotated with gentle but persistent pressure. A positive sign is evidence of apprehension or subluxation. At this point, a "relocation" test is often administered. A posteriorly directed force may be applied to the shoulder. If the candidate's apprehension or pain is reduced, the relocation test is considered to be positive.
- **Load and Shift Test** (Figure VIII-18) checks for capsular laxity. The individual is seated and relaxed, with the shoulder in a neutral position. For the left shoulder exam, the left humeral head is held by the examiner's left hand. The left scapula is stabilized by the examiner's right hand. The left hand loads the joint axially to ensure concentric reduction. The left hand applies anterior and posterior shearing forces. The direction and translation can be graded using a scale of 0-3. Typically, the humeral head moves approximately 25% diameter of

the humeral head. Grade I laxity is indicated by 25-50% subluxation, grade II laxity is indicated by greater than 50% subluxation, and grade III by full subluxation. This is a difficult test for individuals with apprehension and is not recommended for those with a recent instability episode. However, it can be a highly specific test in experienced hands.

- **Hill-Sach's Lesion** is a cortical compression fracture of the posterolateral humeral head caused by humeral head impaction against the anteroinferior part of the glenoid during relocation after a dislocation (Hill & Sachs, 1940). Rotational AP views or axillary radiographs depict this as a flattened area on the posterolateral humeral head (Figure VIII-19). The Hill-Sach's Lesion will be present to varying degrees in the majority of those with prior anterior instability; however, this is not clear evidence of *current* instability. When noted in candidates who have not had prior surgery, referral to the orthopedist may be warranted.

Any of the above signs indicate more than mild instability, resulting in an increased risk of dislocation. A period of observation should be observed before clearance for full duty (see Recommended Evaluation Protocol below).

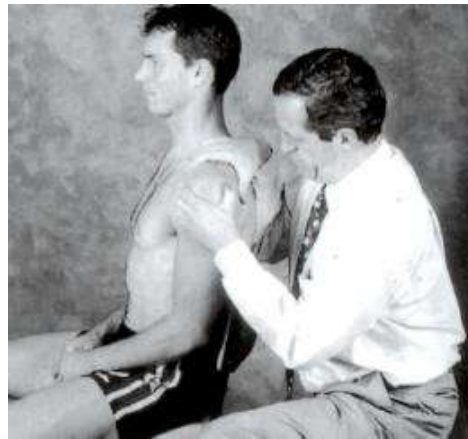

Figure VIII-18. Load and Shift Test for Shoulder Subluxation

Source: Brukner, P. and Khan, K. Clinical Sports Medicine Hardcover. December 19, 2011. McGraw-Hill Australia.

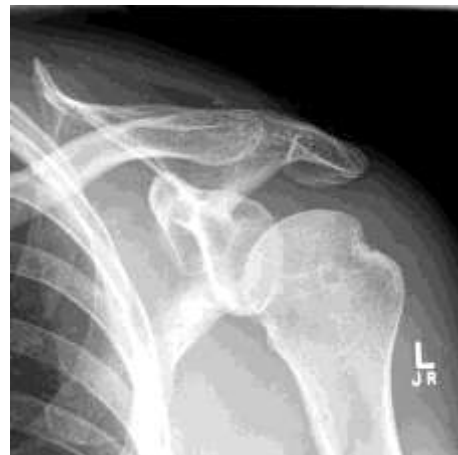

Figure VIII-19. Hill-Sach's Lesion

From Dr. Yuranga Weerakkody and Dr. Frank Gaillard et al. <http://radiopaedia.org/>

DISLOCATION: Recurrence after dislocation is generally very likely unless surgery is performed. Published longitudinal studies have identified several relevant factors:

- **Age** is the *most important*, inversely-related risk factor for recurrence (Hovelius et al., 1996; Rhee, Cho & Cho, 2009; Ramsey et al., 2010; Porcellini et al., 2009, Olds et al., 2015). The glenohumeral joint is inherently more lax in younger persons. Hovelius (1987) conducted the longest term follow-up of patients with shoulder dislocation. Approximately 50% had recurrent instability; however, the risk of recurrence was 50% in age <20 years, 43% from 20-30 years, and only 16% in those >30 years (Hovelius et al., 1996; Hovelius et al., 2008).⁴

⁴ Of note, Hovelius (1996) followed a cohort of 250 patients longitudinally for 25 years; this group had a

- **Time Since Last Recurrence:** Most recurrences occur within two years. However, a substantial proportion of individuals who do well after two years will have recurrence by five years of follow-up. For example, 98% of patients who ultimately have surgery had their first recurrence within five years after the initial dislocation (Hovelius et al., 2008).

Candidates ≤ 40 years old at the time of initial dislocation should be deferred for five years from the date of the last dislocation. Candidates older than 40 years at the time of their first dislocation have a substantially lower recurrence rate. Therefore, a deferral period of two years since the last dislocation is sufficient for candidates ≥ 40 years old.

Although redislocation rate decreases significantly as age increases, the risk of rotator cuff tear during dislocation increases with age.

Candidates should be evaluated for return of strength following a dislocation. Those who have continued weakness require urgent referral to an orthopedist and likely an MRI.

- **Activity level:** Dislocation is associated with physical trauma or athletic participation in about 90% of cases (Hovelius, 1987). In the remaining 10%, the dislocation occurs with movement that a normal shoulder should tolerate. The degree of trauma at the time of dislocation is generally not well-correlated with recurrence risk unless a fracture is present. However, ongoing high-level activity (particularly participation in contact sports) is a clear risk factor for recurrent instability.
- **Radiographic abnormalities:** Evidence of bony injury (either a Hill-Sach's lesion of the humerus or a glenoid rim fracture) is highly correlated with recurrent dislocation. Larger bony injuries on radiographs or MRI are associated with even higher risk. If a clear bony lesion is noted on the radiograph of an individual with ongoing dislocations, the high likelihood of ongoing episodes warrants an MRI and a CT scan along with referral to the orthopedist. Greater tuberosity fractures may also be seen in those with prior dislocations, although these are far less common. A healed greater tuberosity in good position on radiographs will generally not interfere with function (Olds et al., 2015).
- **Gender:** Men are three times more likely than women to suffer from recurrent instability following a first-time traumatic anterior shoulder dislocation. This may be due to the mechanism of injury or with collision sport rule differences between men and women.
- **Hyperlaxity:** Individuals with hyperlaxity are three times more likely to suffer from recurrent instability.

lower rate of recurrence and need for surgery than other studies.

- **Non-operative Treatment** consists of immobilization in a sling for 1-2 weeks, followed by physical therapy. Significantly decreased recurrence rates were found for first-time dislocators who were placed in a brace for three weeks that immobilized the shoulder in adduction and 10° of external rotation (Itoi et al., 2007; Yamamoto et al., 2010; Sullivan et al., 2007). However, a 20% non-compliance rate was observed. While these results were promising, these findings have not been replicated consistently in subsequent studies (Paterson et al., 2010; Tanaka et al., 2010; Hanchard et al., 2014; Vavken et al., 2014; Olds et al., 2015). The current orthopedic strategy still involves a brief immobilization for comfort, followed by progressive mobilization, and a discussion of surgical stabilization versus non-operative care.

Range of motion can begin once the individual is comfortable moving the arm. A referral to physical therapy is beneficial for those with a clear strength deficit, a history of multi-directional instability or generalized laxity, or abnormal scapular motion. Physical therapy has not been shown to be effective in individuals with multiple prior dislocations or notable risk factors (e.g. age and bony injury). However, it may be quite effective in regaining motion in lower risk individuals or in regaining strength and motion after an event.

- **Number of recurrences** is the most significant factor in predicting future instability. Younger individuals with prior dislocations have a 70-90% risk of further instability (Hovelius et al., 2008; Boileau et al., 2010; Dumont et al., 2011). This risk increases with two or more dislocations. Young, highly-active individuals generally need surgical stabilization after two dislocations due to ongoing instability and disability.

Those who have experience a single dislocation may do well without surgical treatment depending on their risk factors for recurrences (see above). Individuals <30 years old who have experienced two or more dislocations are at high risk of additional dislocation without surgical treatment (Hovelius et al., 2008).

- **Surgery:** Shoulder stabilization involves repairing the torn labrum and tightening or shifting the stretched capsule. Arthroscopic stabilization is more common, although open stabilization is also effective. Some individuals may lose flexibility after shoulder stabilization, particularly in external rotation. However, significant motion loss should not occur, and if found, warrants referral to physical therapy or to an orthopedist if chronic and severe. Return to full field activity is expected 6-9 months after shoulder stabilization surgery (Dumont et al., 2011). Candidates with prior shoulder stabilization should be deferred for 1-2 years after surgery, since most recurrences occur during this time period (Hovelius et al., 2008). Recurrence after surgical stabilization is more likely for those < 20 years old at the time of surgery and who experienced a bony injury on either the humeral or glenoid side (Boileau et al., 2010; Dumont et al., 2011).

The presence of severe degenerative joint disease must also be evaluated. Degenerative joint disease can be expected in 25-30% of individuals with prior recurrent instability at long-term follow up, even if treated operatively (Harris et al., 2013). These candidates have a substantially higher risk of disability from the

unavoidable trauma of shotgun recoil, wrestling, or other job functions. Individuals with a high number of prior shoulder dislocations and those with severe loss of mobility should have radiographs to evaluate degenerative joint disease.

b) Recommended Evaluation Protocol:

Candidates with a history of subluxation should be questioned regarding any symptoms referable to the arm such as pain, numbness, or weakness. Some candidates will report a history of acromioclavicular separation when asked about dislocations. A careful history and having the candidate point to the location of pain ("Fortin test") will usually clarify the diagnosis. Those with a history of an unstable shoulder should be asked the following four questions (Thangarajah & Lambert, 2015):

- *Was your first dislocation caused by a specific injury?*
- *How old were you when you first dislocated your shoulder?*
- *How many times has your shoulder dislocated?*
- *In which way does your shoulder dislocate, anterior (>90% of cases), posterior or multi-directional? (Individuals often know which way their shoulder dislocates).*

Examination should include testing for apprehension, as discussed earlier. If doubt remains, a radiographic series may show a Hill-Sachs and/or Bankart lesion or AC separation. Radiographs should include A-P and axillary views. To avoid exposing the candidate to unnecessary radiation, radiographs should be deferred until it has been determined the candidate is otherwise acceptable. The radiograph can then be used to examine the condition of any post-surgical hardware and the extent of degenerative changes.

Record review is important. Risk factors should be carefully assessed.

HISTORY OF SUBLUXATION ONLY

GROUP I: No history of arm pain or weakness, negative apprehension sign and no Hill-Sachs and/or Bankart lesion on x-ray

In general, no restrictions are warranted. However, the candidate's ability to tolerate the weight training required in the academy should be considered.

GROUP II: History of arm pain or weakness, or positive apprehension sign, or Hill-Sachs and/or Bankart lesion on x-ray

Candidates should be restricted from wrestling and overhead activities for a period of two years from the date of their last episode of arm symptoms. The presence of an apprehension sign or Hill-Sachs and/or Bankart lesion warrants an observation period of two years. Referral for further rehabilitation or for orthopedic evaluation may also be warranted.

HISTORY OF ANTERIOR DISLOCATION

GROUP I: Primary dislocation at age >40, or s/p surgery (any age)

Candidates should be restricted from wrestling and overhead movement activities for a period of two years from the date of their last dislocation or surgery.

GROUP II: Primary dislocation first occurring at age <40

Candidates should be restricted from wrestling and overhead movement activities for a period of five years from the date of the last dislocation. Those with multiple prior dislocations should be referred to an orthopedist for possible surgical treatment.

16) Rotator Cuff Disease

a. General Considerations:

The rotator cuff consists of a set of four muscle-tendon units attaching on the greater and lesser tuberosities of the humerus (Figure VIII-20). From anterior to posterior, the muscles are the subscapularis, supraspinatus, infraspinatus, and teres minor.

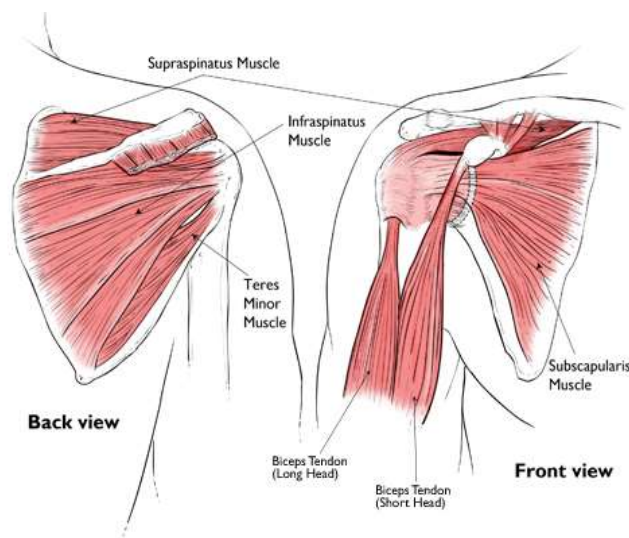


Figure VIII-20. Diagram of the two biceps muscle tendons and the four muscles of the rotator cuff: subscapularis, supraspinatus, infraspinatus and teres minor.

Reproduced with permission from *The Body Almanac*. ©American Academy of Orthopaedic Surgeons, 2003, as adapted for *OrthoInfo*.

The rotator cuff stabilizes the shoulder joint as the arm moves in space, and as such it is critical in overhead movements and lifting.

Disease of the rotator cuff is very common with advancing age. Rotator cuff tendonitis or tears are also seen in individuals who do repetitive overhead work, such as laborers and athletes in sports such as tennis and volleyball. There is a wide spectrum of rotator cuff diseases, from simple tendonosis or strains to chronic tendonitis, from partial tears to full-thickness tears (Lewis, 2010). Impingement refers to irritation of the rotator cuff and surrounding bursa as the arm is elevated and abducted.

Treatment and prognosis are highly dependent on the degree of rotator cuff injury.

Treatment: Most individuals with rotator cuff tendonitis or partial thickness tears respond well to non-operative treatment (Smith & Smith, 2010). This may include activity modification (avoidance of overhead activity and heavy lifting), NSAIDs, and physical therapy. Individuals who do not respond to initial treatment or whose acute symptoms are indicative of a full-thickness rotator cuff tear (e.g., significant

weakness or traumatic injury resulting in weakness) should be referred to an orthopaedist to evaluate for structural damage to the rotator cuff.

Most individuals without a full-thickness tear will not require surgery. In a minority of cases, a debridement of the rotator cuff, bursectomy, and subacromial decompression can be performed to relieve symptoms, although this procedure has become less common as non-surgical rehabilitation techniques have improved (Pedowitz et al., 2011).

Surgical repair of small and medium-sized rotator cuff tears is more effective than physical therapy; however, the difference in outcomes between surgical and non-surgical treatment are small and may be below clinical importance. Although rotator cuff surgery is not considered urgent, in approximately one-third of cases, neglected tears over time can become larger and have worse surgical outcomes (Mall et al., 2010; Moosmayer et al., 2014). Individuals undergoing rotator cuff repair can return to work and sports, including lifting, approximately 4-6 months after surgery (Burns & Snyder, 2008; Lin et al., 2013; Krishnan et al., 2008; Hawkins et al., 1999; Acevedo et al., 2014). In one study, individuals receiving worker's compensation benefits required an average of eight months before returning to gainful employment (Iannotti et al., 1996). However, Krishnan et al. (2008) reported no difference in return to work compared to individuals without worker's compensation benefits.

b. Recommended Evaluation Protocol:

Individuals with rotator cuff disease (RCD) will often complain of pain with overhead movements, difficulty lifting, and pain along the lateral shoulder or deltoid. Pain may extend toward but not beyond the elbow. Occasionally pain can extend to the hand with rotator cuff disease, but it is uncommon and the symptoms usually do not follow a specific dermatomal distribution. More commonly, pain down the entire arm is suspicious for cervical spine disease. The individual should be questioned about symptom duration and severity and specific limitations, as well as weakness following a specific injury or fall, as this may indicate a more serious tear.

Physical Exam: It may be difficult to detect a small tear in an individual with severe pain, or conversely in individuals with a high level of strength.

▪ **Impingement Tests** (Figures VIII-21a/b):

- a. Neer: Arm is elevated and internally rotated toward ear; pain is elicited when positive

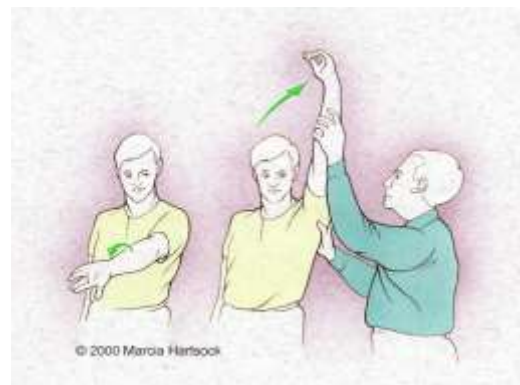

Figure VIII-21a. Neer's Sign
Illustration © Marcia Hartssock

- b. Hawkins: Arm is abducted, forward flexed and internally rotated; pain is elicited when positive

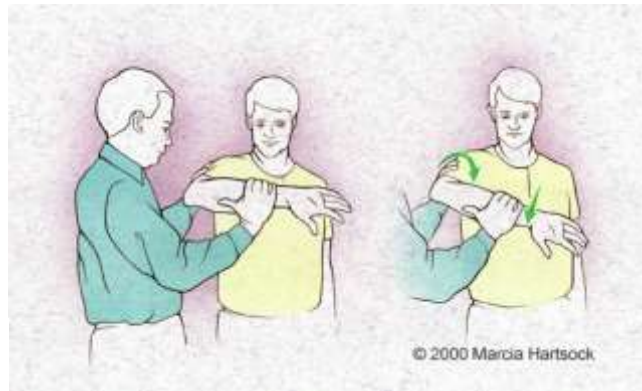


Figure VIII-21b. Hawkins Sign
Illustration © Marcia Hartsock

- **Supraspinatus Test/Jobe's/"Empty Can" Test** (Figure VIII-22): Arm is held in mid- flexion, abduction and internal rotation and examiner pushes downward on the arm; pain and weakness are elicited when positive.

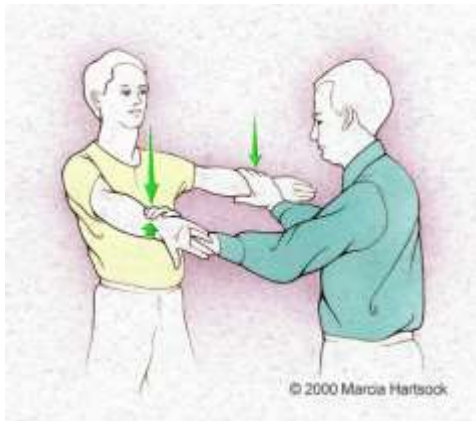


Figure VIII-22. Supraspinatus Testing/Jobe's/"Empty Can" Test
Illustration © Marcia Hartsock

- **Infraspinatus and Teres Minor** (Figure VIII-23): With the elbow flexed at 90° and at the side, external rotation is resisted; pain and weakness are elicited when positive.

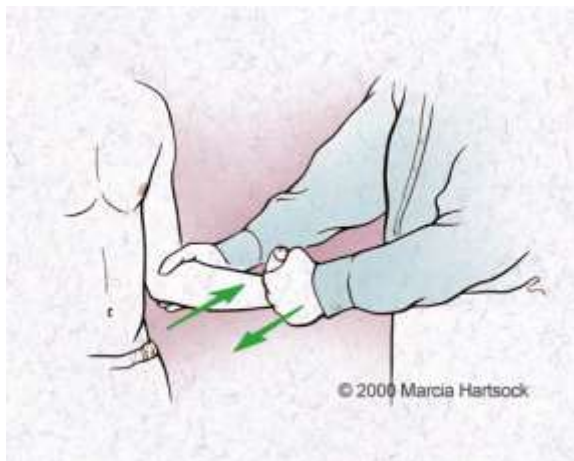


Figure VIII-23. Infraspinatus Testing. The examiner applies a medially directed force while the candidate is instructed to resist.
Illustration © Marcia Hartsock

- **Subscapularis/Gerber's Lift-off Test** (Figure VIII-24): The hand is brought back onto the flank and then lifted off posteriorly; the individual should be able to keep the hand elevated off the back.

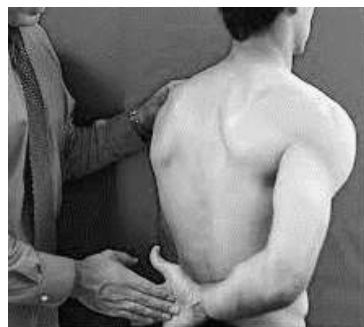

Figure VIII-24.
Subscapularis/Gerber's Lift-off Test

Imaging is indicated in individuals with ongoing pain that does not respond to rest and NSAIDs, or after an acute injury. A shoulder x-ray series generally includes an AP, axillary lateral, and Bigliani or Y view. The Bigliani view allows visualization of the acromial morphology which may predispose to impingement or rotator cuff disease when hooked or down-sloping. Rotational views are generally not helpful in rotator cuff disease (unlike in instability where a Hill-Sachs lesion is often present). MRI is the most sensitive and specific test for rotator cuff disease. Contrast is not needed for visualization of the rotator cuff. If significant weakness is noted on exam, MRI may be indicated to rule out rotator cuff tear. On the MRI, the size of the tear, degree of retraction, and degree of muscle atrophy (indicating chronicity) are noted. In those > 40 years old, some degenerative change in the rotator cuff is common; however, full-thickness tears are generally symptomatic in active individuals and usually require surgical treatment. The [Rotator Cuff Quality-of-Life Measure](#) (a disease-specific, quality-of-life measurement tool for individuals with rotator cuff disease) can help predict which individuals respond best to nonoperative treatment of a chronic full-thickness rotator cuff tear (Boorman et al., 2014).

For those few individuals with the signs and symptoms of an acute, full-thickness rotator cuff tear (e.g., significant weakness or traumatic injury resulting in weakness), urgent MRI and urgent orthopedic surgical evaluation is indicated. For others, a non-operative course involving physical therapy and one-to-two sub-acromial cortisone injections is indicated (Escamilla et al., 2014). Candidates should be restricted from wrestling and overhead activities during this time. Individuals who do not respond satisfactorily to this treatment course should be considered for MRI and orthopedic surgical evaluation.

17) Finger Amputations/Arthrosis

This condition is not uncommon among candidates. Because an officer's life may depend on his/her ability to resist firearm "take-away," the ability to tightly grip and handle a baton or firearm must be carefully evaluated. This determination generally can be made after examination.

Amputations that do not extend beyond the distal interphalangeal joint rarely cause impairment. Objective testing of grip strength with a dynamometer (e.g. Jamar, Lafayette Instrument Company, USA) is helpful (Roberts et al., 2011). Although, a guideline for minimum grip strength is unavailable, someone whose strength is symmetrical after considering hand dominance (+/- about 10%) does not pose a problem.

In difficult cases where there is some question as to the significance of objective weakness or deformity, a special "handgun and baton handling" assessment by the training academy experts should be considered in the determination.

18) Carpal Tunnel Syndrome

a. General Considerations

Carpal tunnel syndrome (CTS) is the most common entrapment neuropathy. It is caused by compression of the median nerve under the transverse carpal ligament that provides the "roof" of the carpal tunnel in the palmar wrist. This results in a median nerve neuropathy. CTS patients complain of hand pain, numbness and tingling which may or may not be limited to the median nerve dermatome.

Radiation of symptoms up into the forearm toward the shoulder is not uncommon. Nocturnal exacerbation is typical, presumably as a result of the wrist being held in prolonged flexion or extension during sleep. Predisposing factors include previous Colles' fracture, rheumatoid arthritis, diabetes, gout, pregnancy, thyroid conditions, multiple myeloma and tuberculosis. However, most individuals are otherwise healthy.

With time, nocturnal symptoms may start to occur during the day with progressive frequency in association with repetitive use of the hands. Individuals with CTS complain of diminished hand sensation, reduced coordination and an inability to manipulate small objects (e.g., buttoning clothes) and of occasionally dropping objects, such as coffee cups. Individuals also notice burning sensations, a feeling of fullness, and inability to make a tight fist.

b. Recommended Evaluation Protocol

Physical examination includes a neurological examination of the hand, with particular focus on finger flexor strength (a median nerve mediated function). Symptoms may be exacerbated by tapping on the carpal tunnel of the wrist (Tinel's sign) or by prolonged wrist flexion (Phalen's sign). These special tests have variable discriminatory power, but can help support the clinical diagnosis (Dumitru et al., 2001).

The best objective diagnostic test is an electrodiagnostic evaluation with nerve conduction studies and needle electromyography. Ultrasound can confirm the diagnosis of carpal tunnel syndrome with equal sensitivity to electrodiagnostic testing in certain individuals, although with inferior ability to grade carpal tunnel severity and limited ability to evaluate other possible comorbid conditions (such as a cervical radiculopathy, ulnar neuropathy or peripheral poly-neuropathy) (Fowler et al., 2014).

Although several procedures have been established to diagnose and rate the severity of carpal tunnel syndrome, there are no universally accepted criteria or standards. The overall diagnosis is fundamentally a clinical decision. Severity can be rated as *mild* (median sensory nerve abnormalities), *moderate* (median sensory and motor nerve abnormalities), and *severe* (median sensory and motor nerve

abnormalities, along with needle EMG abnormalities) (Dumitru et al., 2001). A reasonable treatment approach utilizes ~6 weeks of night-time splinting for mild cases, splinting and consideration of a steroid injection for moderate cases, and surgery for severe cases or cases which fail to resolve satisfactorily with non-operative care.

Symptoms often recur despite non-operative treatment (Page, O'Connor et al., 2012; Page, Massy-Westropp et al., 2012). Given its low complication rate and good outcomes in well-selected individuals, surgery is often the most expedient treatment route (Dumitru et al., 2001). After carpal tunnel release surgery, individuals generally return to work in an average of four weeks, although the range is between 5-45 days, depending on work demand, surgical technique, individual's psychological makeup, and social and economic factors (Sanati et al., 2011). On average, grip and pinch strength return by about two months after surgery (AAOS, 2009). The syndrome can occasionally recur and may require additional surgery.

19) Retained Orthopedic Hardware

An assortment of screws, nails, rods and plates are often used in orthopedic surgery. In the setting of a healed fracture, there is controversy about routine hardware removal because implant removal may be more challenging and complication-prone than the initial surgery.

Elective hardware removal may be requested due to concerns about the systemic and local effects of retained implants. However, the universal retention or removal of hardware does not appear to have a significant effect on subsequent fracture risk, pain relief, cancer risk, or airport travel problems (metal detectors) (Busam et al., 2006).

Hardware must be removed in the setting of infection, implant failure, non-union and soft-tissue compromise. Additionally, palpable hardware may increase the risk of serious skin breakdown with minor trauma. Implants with nickel or chromium composition can cause allergic hypersensitivity responses or aseptic loosening in a small segment of the population, particularly among those with metal-on-metal hip arthroplasty.

A physical exam and a radiograph of the area are necessary. If hardware is palpable or there is evidence of implant failure or migration, an orthopedist should be consulted regarding the benefits and risks of removal. The candidate's compliance is required to be considered for appointment.

REFERENCES

- Acevedo, D.C., Paxton, E.S., Williams, G.R., & Abboud, J.A. (2014). A survey of expert opinion regarding rotator cuff repair. *J Bone Joint Surg Am*, 96, e123.
- Aebi, M. (2005). The adult scoliosis. *Eur Spine J*, 14, 925-48.
- Agabegi, S.S. & Fischgrund, J.S. (2010). Contemporary management of isthmic spondylolisthesis: pediatric and adult. *Spine J*, 10, 530-43.
- Alaia, M.J., Cohn, R.M., & Strauss, E.J. (2014). Patellar instability. *Bull Hosp Jt Dis*, 72, 6-17.
- Alfieri, A., Gazzeri, R., Prell, J., & Rollinghoff, M. (2013). The current management of lumbar spondylolisthesis. *J Neurosurg Sci*, 57, 103-13.
- American Academy of Orthopaedic Surgeons [AAOS] (2008). *The Burden of Musculoskeletal Diseases in the United States: Prevalence, Societal and Economic Cost*. 1st ed. Rosemont, IL.
- American Academy of Orthopaedic Surgeons [AAOS]. (2009). *Carpal Tunnel Syndrome*. <<http://www.orthoinfo.aaos.org/topic.cfm?topic=a00005>>.
- American Academy of Orthopaedic Surgeons [AAOS]. (2012a). *Face Off, ACL Return to Play*. <<http://www.aaos.org/news/aaosnow/dec12/clinical7.asp>>.
- American Academy of Orthopaedic Surgeons [AAOS]. (2012b). *Informed Patient - Anterior Cruciate Ligament Reconstruction*. <<http://www5.aaos.org/icm/PrintModule.cfm?module=icm004>>.
- Amis, A.A. (2007). Current concepts on anatomy and biomechanics of patellar stability. *Sports Med Arthrosc*, 15, 48-56.
- Anand, N., Baron, E.M., Khandehroo, B., & Kahwaty, S. (2013). Long-term 2- to 5-year clinical and functional outcomes of minimally invasive surgery for adult scoliosis. *Spine*, 38, 1566-75.
- Ang, B.O., Monnier, A., & Harms-Ringdahl, K. (2009). Neck/shoulder exercise for neck pain in air force helicopter pilots: a randomized controlled trial. *Spine*, 34, E544-51.
- Apel, D.M., Lorenz, M.A., & Zindrick, M.R. (1989). Symptomatic spondylolisthesis in adults: four decades later. *Spine*, 14, 345-8.
- Ardern, C.L., Taylor, N.F., Feller, J.A, Whitehead, T.S., & Webster, K.E. (2013). Psychological responses matter in returning to preinjury level of sport after anterior cruciate ligament reconstruction surgery. *Am J Sports Med*, 41, 1549-58.
- Ardern, C.L., Taylor, N.F., Feller, J.A, Whitehead, T.S., & Webster, K.E. (2015). Sports participation 2 years after anterior cruciate ligament reconstruction in athletes who had not returned to sport at 1 year: a prospective follow-up of physical function and psychological factors in 122 athletes. *Am J Sports Med*, 43, 848-56.
- Ardern, C.L., Webster, K.E., Taylor, N.F., & Feller, J.A. (2011). Return to sport following anterior cruciate ligament reconstruction surgery, a systematic review and meta-analysis of the state of play. *Br J Sports Med*, 45, 596-606.

Atlas, S.J., Keller, R.B., Wu, Y.A., Deyo, R.A., & Singer, D.E. (2005). Long-term outcomes of surgical and nonsurgical management of sciatica secondary to a lumbar disc herniation: 10 year results from the Maine lumbar spine study. *Spine*, 30, 927-35.

Axen, I. & Leboeuf-Yde, C. (2013). Trajectories of low back pain. *Best Pract Res Clin Rheumatol*, 27, 601-12.

Azer, N.M., Winalski, C.S., & Minas, T. (2004). MR imaging for surgical planning and postoperative assessment in early osteoarthritis. *Radiol Clin North Am*, 42, 43-60.

Baker, R.L., Souza, R.B., & Fredericson, M. (2011). Iliotibial band syndrome, soft tissue and biomechanical factors in evaluation and treatment. *PM R*, 3, 550-61.

Barber, S.D., Noyes, F.R., Mangine, R.E., McCloskey, J.W., & Hartman, W. (1990). Quantitative assessment of functional limitations in normal and anterior cruciate ligament-deficient knees. *Clin Orthop Relat Res*, 204-14.

Barber-Westin, S.D. & Noyes, F.R. (2011a). Factors used to determine return to unrestricted sports activities after anterior cruciate ligament reconstruction. *Arthroscopy*, 27, 1697-705.

Barber-Westin, S.D. & Noyes, F.R. (2011b). Objective criteria for return to athletics after anterior cruciate ligament reconstruction and subsequent reinjury rates, a systematic review. *Phys Sportsmed*, 39, 100-10.

Bas, T., Franco, N., Bas, P., & Bas, J.L. (2012). Pain and disability following fusion for idiopathic adolescent scoliosis: prevalence and associated factors. *Evid Based Spine Care J*, 3, 17-24.

Bassewitz, H. & Herkowitz, H. (2001). Lumbar stenosis with spondylolisthesis: current concepts of surgical treatment. *Clin Orthop Relat Res*, 54-60.

Bauer, M., Feeley, B.T., Wawrzyniak, J.R., Pinkowsky, G., & Gallo, R.A. (2014). Factors affecting return to play after anterior cruciate ligament reconstruction, a review of the current literature. *Phys Sportsmed*, 42, 71-9.

Benoist, M. (2002). The natural history of lumbar disc herniation and radiculopathy. *Joint Bone Spine*, 69, 155-60.

Berner, J.G., et al. (1985). Analysis of the Physical Demands of California Patrol Officers. Unpublished Technical Report, Commission on Peace Officer Standards and Training (POST).

Beutler, W.J., Fredrickson, B.E., Murtland, A., Sweeney, C.A., Grant, W.D. & Baker, D. (2003). The natural history of spondylolysis and spondylolisthesis: 45-year follow-up evaluation. *Spine*, 28, 1027-35.

Bianchi, S. & Martinoli, C. (1999). Detection of loose bodies in joints. *Radiol Clin North Am*, 37, 679-90.

Bigos, S.J., Battie, M.C., Spengler, D.M., et al. (1991). A prospective study of work perceptions and psychosocial factors affecting the report of back injury. *Spine*, 16, 1-6.

Bizzini, M., Gorelick, M., & Drobny, T. (2006). Lateral meniscus repair in a professional ice hockey goaltender: a case report with a 5-year follow-up. *J Orthop Sports Phys Ther*, 36, 89-100.

- Blond, L. & Hansen, L. (1998). Patellofemoral pain syndrome in athletes: a 5.7-year retrospective follow-up study of 250 athletes. *Acta Orthop Belg*, 64, 393-400.
- Blondel, B., Wickman, A.M., Apazidis, A., Lafage, V.C., Schwab, F.J., & Bendo, J.A. (2013). Selection of fusion levels in adults with spinal deformity: an update. *Spine J*, 13, 464-74.
- Boden, S., Davis, D., Dina T., Patronas, N., & Wiesel S. (1990). Abnormal magnetic-resonance scans of the lumbar spine in asymptomatic subjects. A prospective investigation. *J Bone Joint Surg Am*, 72, 403-8.
- Boden, S., McCowin, P., Davis, D., Dina, T., Mark, A., & Wiesel, S. (1990). Abnormal magnetic-resonance scans of the cervical spine in asymptomatic subjects. A prospective investigation. *J Bone Joint Surg Am*, 72, 1178-84.
- Bogduk, N. (1999). Regional musculoskeletal pain. The neck. *Baillieres Best Pract Res Clin Rheumatol*, 13, 261-85.
- Boileau, P., Mercier, N., Roussanne, Y., Thelu, C.E., & Old, J. (2010). Arthroscopic Bankart-Bristow-Latarjet procedure: the development and early results of a safe and reproducible technique. *Arthroscopy*, 26, 1434-50.
- Bonamo J.J., Fay, C. & Firestone, T. (1990). The conservative treatment of the anterior cruciate deficient knee. *Am J Sports Med*, 18, 618-23.
- Bonanno, D.R., Murley, G.S., Munteanu, S.E., Landorf, K.B., & Menz, H.B. (2015). Foot orthoses for the prevention of lower limb overuse injuries in naval recruits: study protocol for a randomised controlled trial. *J Foot Ankle Res*, 8, 51.
- Bono, C.M., Ghiselli, G., Gilbert, T.J. et al., (2011). An evidence-based clinical guideline for the diagnosis and treatment of cervical radiculopathy from degenerative disorders. *Spine J*, 11, 64-72.
- Boorman, R.S., More, K.D., Hollinshead, R.M., et al. (2014). The rotator cuff quality-of-life index predicts the outcome of nonoperative treatment of patients with a chronic rotator cuff tear. *J Bone Joint Surg Am*, 96, 1883-8.
- Borenstein, D.G, O'Mara, J.W., Jr., Boden SD., et al. (2001). The value of magnetic resonance imaging of the lumbar spine to predict low-back pain in asymptomatic subjects: a seven-year follow-up study. *J Bone Joint Surg Am*, 83-A, 1306-11.
- Briggs, K.K., Lysholm, J., Tegner, Y., Rodkey, W.G., Kocher, M.S., & Steadman, J.R. (2009). The reliability, validity, and responsiveness of the Lysholm score and Tegner activity scale for anterior cruciate ligament injuries of the knee: 25 years later. *Am J Sports Med*, 37, 890-7.
- Bron, J.L., van Royen, B.J., & Wuisman, P.I. (2007). The clinical significance of lumbosacral transitional anomalies. *Acta Orthop Belg*. 73, 687-95.
- Burns, J.P. & Snyder, S.J. (2008). Arthroscopic rotator cuff repair in patients younger than fifty years of age. *J Shoulder Elbow Surg*, 17, 90-6.
- Busam, M.L., Esther, R.J., & Obrebsky, W.T. (2006). Hardware removal: indications and expectations. *J Am Acad Orthop Surg*, 14, 113-20.

Camp, C.L., Stuart, M.J., Krych, A.J., et al. (2013). CT and MRI measurements of tibial tubercle-trochlear groove distances are not equivalent in patients with patellar instability. *Am J Sports Med*, 41, 1835-40.

Carroll, L.J., Hogg-Johnson, S., Cote, P., et al. (2008). Course and prognostic factors for neck pain in workers: results of the Bone and Joint Decade 2000-2010 Task Force on Neck Pain and Its Associated Disorders. *Spine*, 33, S93-100.

Chang, D.G. & Date, E. (2009). Electrodiagnostic Evaluation of Acute and Chronic Pain Syndromes. In J. Ballantyne, J. Rathmell, & S. Fishman (Eds.), *Bonica's Management of Pain*. 4th Ed. (pp. 223-33). Philadelphia: Lippincott Williams & Wilkins.

Chang, D.G, Kim, C.W., & Garfin, S.R. (2008). Orthopedic Perspective: The Spine in Sports. (2008). In R.A. Pedowitz, C.B. Chung & D. Resnick (Eds.), *Magnetic Resonance Imaging in Orthopaedic Sports Medicine* (pp. 135-56). New York: Springer.

Chiodo, A., Haig, A.J., Yamakawa, K.S., Quint, D., Tong, H., & Choksi, V.R. (2007). Needle EMG has a lower false positive rate than MRI in asymptomatic older adults being evaluated for lumbar spinal stenosis. *Clin Neurophysiol*, 118, 751-6.

Cho, S.C., Ferrante, M.A., Levin, K.H., Harmon, R.L. & So, Y.T. (2010). Utility of electrodiagnostic testing in evaluating patients with lumbosacral radiculopathy: An evidence-based review. *Muscle Nerve*, 42. 276-82.

Chou, R., Qaseem, A., Snow, V., et al. (2007). Diagnosis and treatment of low back pain: a joint clinical practice guideline from the American College of Physicians and the American Pain Society. *Ann Intern Med*, 147, 478-91.

Christensen, S.T. & Hartvigsen, J. (2008). Spinal curves and health: a systematic critical review of the epidemiological literature dealing with associations between sagittal spinal curves and health. *J Manipulative Physiol Ther*, 31, 690-714.

Collins, N.J., Bierma-Zeinstra, S.M., Crossley, K.M., van Linschoten, R.L., Vicenzino, B., & van Middelkoop, M. (2013). Prognostic factors for patellofemoral pain: a multicentre observational analysis. *Br J Sports Med*, 47, 227-33.

Colvin, A.C. & West, R.V. (2008). Patellar instability. *J Bone Joint Surg Am*, 90, 2751-62.

Concannon, L.G., Harrast, M.A., & Herring, S.A. (2012). Radiating upper limb pain in the contact sport athlete: an update on transient quadriplegia and stingers. *Curr Sports Med Rep*, 11, 28-34.

Cote, P., van der Velde, G., Cassidy, J.D., et al. (2008). The burden and determinants of neck pain in workers: results of the Bone and Joint Decade 2000-2010 Task Force on Neck Pain and Its Associated Disorders. *Spine*, 33, S60-74.

Cox, J.S. (1981). The fate of the acromioclavicular joint in athletic injuries. *Am J Sports Med*, 9, 50-3.

Daniel, D.M., ed. (1990). *KT-1000 Anterior-posterior Displacement Measurements*. New York: Raven Press.

- Daniel, D. M., Akeson, W. H., & O'Connor, J. J. (1990). *Knee Ligaments: Structure, Function, Injury, and Repair*. New York, NY:Raven Press.
- Daniel, D.M., Stone, M.L., & Riehl, B. (1990). Ligament surgery: the evaluation of results. The fate of unoperated knee ligament injuries. In D.M. Daniel, W.H., Akeson, & J.J. O'Connor, eds. *Knee ligaments: structure, function, injury, and repair*, (521-534), New York, NY: Raven Press.
- Daniel, D.M., Stone, M.L., & Riehl, B. (1990). Ligament Surgery; the evaluation of results. In: Daniel D.M., Akeson W.H., O'Connor J.J., eds. *Knee Ligaments: Structure, Function, Injury and Repair*. New York: Raven Press, p 558.
- DeFranco, M.J. & Bach, B.R., Jr. (2009). A comprehensive review of partial anterior cruciate ligament tears. *J Bone Joint Surg Am*, 91, 198-208.
- DeHaven, K.E. & Lintner, D.M. (1986). Athletic injuries: comparison by age, sport, and gender. *Am J Sports Med*, 14, 218-24.
- Derasari, A., Brindle, T.J., Alter, K.E. & Sheehan, F.T. (2010). McConnell taping shifts the patella inferiorly in patients with patellofemoral pain: a dynamic magnetic resonance imaging study. *Phys Ther*, 90, 411-9.
- Devereaux, M.D. & Lachmann, S.M. (1984). Patello-femoral arthralgia in athletes attending a Sports Injury Clinic. *Br J Sports Med*, 18, 18-21.
- Deville, W.L., van der Windt, D.A., Dzaferagic, A., Bezemer, P.D., & Bouter, L.M. (2000). The test of Lasegue: systematic review of the accuracy in diagnosing herniated discs. *Spine*, 25, 1140-7.
- DeWald, C.J., Vartabedian, J.E., Rodts, M.F., & Hammerberg, K.W. (2005). Evaluation and management of high-grade spondylolisthesis in adults. *Spine*, 30, S49-59.
- Deyo, R. & Weinstein, J. (2001). Low back pain. *NEJM*, 344, 363-70.
- Dias, J.J., Steingold, R.F., Richardson, R.A., Tesfayohannes, B., & Gregg, P.J. (1987). The conservative treatment of acromioclavicular dislocation. Review after five years. *J Bone Joint Surg Br*, 69, 719-22.
- Donaldson, W.F., 3rd, Warren, R.F., & Wickiewicz, T. (1985). A comparison of acute anterior cruciate ligament examinations. Initial versus examination under anesthesia. *Am J Sports Med*, 13, 5-10.
- Draper, C.E., Besier, T.F., Santos, J.M., et al. (2009). Using real-time MRI to quantify altered joint kinematics in subjects with patellofemoral pain and to evaluate the effects of a patellar brace or sleeve on joint motion. *J Orthop Res*, 27, 571-7.
- Dumitru, D., Amato, A., Zwarts, M., eds. (2001). *Electrodiagnostic Medicine*. 2nd ed. Philadelphia: Hanley & Belfus.
- Dumont, G.D., Russell, R.D., & Robertson, W.J. (2011). Anterior shoulder instability: a review of pathoanatomy, diagnosis and treatment. *Curr Rev Musculoskelet Med*, 4, 200-7.
- Eck, J.C. & Riley, L.H. (2004). Return to play after lumbar spine conditions and surgeries. *Clin Sports Med*, 23, 367-79, viii.

- Eisele, S.A. (1991). A precise approach to anterior knee pain. *Phys Sportsmed*, 19, 127-39.
- Ellsasser, J.C., Reynolds, F.C. & Omohundro, J.R. (1974). The non-operative treatment of collateral ligament injuries of the knee in professional football players. An analysis of seventy-four injuries treated non-operatively and twenty-four injuries treated surgically. *J Bone Joint Surg Am*, 56, 1185-90.
- Epstein, N.E. (2003). Laminectomy for cervical myelopathy. *Spinal Cord*, 41, 317-27.
- Epstein, N.E. (1998). Decompression in the surgical management of degenerative spondylolisthesis: advantages of a conservative approach in 290 patients. *J Spinal Disord*, 11, 116-23.
- Escamilla, R.F., Hooks, T.R. & Wilk, K.E. (2014). Optimal management of shoulder impingement syndrome. *Open Access J Sports Med*, 5, 13-24.
- Ferber, R., Kendall, K.D., & McElroy, L. (2010). Normative and critical criteria for iliotibial band and iliopsoas muscle flexibility. *J Athl Train*, 45, 344-8.
- Ferrari, R. & Russell, A.S. (2003). Regional musculoskeletal conditions: neck pain. *Best Pract Res Clin Rheumatol*, 17, 57-70.
- Fithian, D.C., Paxton, E.W., Stone, M.L. et al. (2004). Epidemiology and natural history of acute patellar dislocation. *Am J Sports Med*, 32, 1114-21.
- Fowler, J.R., Munsch, M., Tosti, R., Hagberg, W.C., & Imbriglia, J.E. (2014). Comparison of ultrasound and electrodiagnostic testing for diagnosis of carpal tunnel syndrome: study using a validated clinical tool as the reference standard. *J Bone Joint Surg Am*, 96, e148.
- Fredericson, M. & Yoon, K. (2006). Physical examination and patellofemoral pain syndrome. *Am J Phys Med Rehabil*, 85, 234-43.
- Frizziero, A., Ferrari, R., Giannotti, E., Ferroni, C., Poli, P., & Masiero, S. (2012). The meniscus tear. State of the art of rehabilitation protocols related to surgical procedures. *Muscles Ligaments Tendons J*, 2, 295-301.
- Froelich, J.M. & Hillard-Sembell, D. (2009). Symptomatic loose bodies of the knee located in a popliteal cyst. *Orthopedics*, 32, 918.
- Fulkerson, J.P. (2004). *Disorders of the Patellofemoral Joint* 4th ed. Baltimore, MD: Lippincott Williams & Wilkins.
- Fulkerson, J.P. & Edgar, C. (2013). Medial quadriceps tendon-femoral ligament: surgical anatomy and reconstruction technique to prevent patella instability. *Arthrosc Tech*, 5, 2, e125-8.
- Gibson, J.N. & Waddell, G. (2007). Surgical interventions for lumbar disc prolapse: updated Cochrane Review. *Spine*, 32, 1735-47.
- Glassman, S.D., Berven, S., Bridwell, K., Horton, W., & Dimar, J.R. (2005). Correlation of radiographic parameters and clinical symptoms in adult scoliosis. *Spine*, 30, 682-8.
- Gore, D.R. (2001). Roentgenographic findings in the cervical spine in asymptomatic persons: a ten-year follow-up. *Spine*, 26, 2463-6.

Gotze, C., Liljenqvist, U.R., Slomka, A., Gotze, H.G., & Steinbeck, J. (2002). Quality of life and back pain: outcome 16.7 years after Harrington instrumentation. *Spine*, 27, 1456-64.

Gray, J.C. (1999). Neural and vascular anatomy of the menisci of the human knee. *J Orthop Sports Phys Ther*, 29, 23-30.

Greene, H.S., Cholewicki, J., Galloway, M.T., Nguyen, C.V., & Radebold, A. (2001). A history of low back injury is a risk factor for recurrent back injuries in varsity athletes. *Am J Sports Med*, 29, 795-800.

Grimm, B.D., Leas, D.P., & Glaser, J.A. (2013). The utility of routine postoperative radiographs after cervical spine fusion. *Spine J*, 13, 764-9.

Grob, D., Dvoržak, J., & Gilliar, W. (2008). Selected Clinical Syndromes of the Spine. In J. Dvoržak, V. Dvoržak, W. Gilliar, W. Schneider, H Spring, T. Tritschler, eds., *Musculoskeletal Manual Medicine: Diagnosis and Treatment* (pp. 214-330). New York: Thieme.

Gruskay, J.A., Webb, M.L., & Grauer, J.N. (2014). Methods of evaluating lumbar and cervical fusion. *Spine J*, 14, 531-9.

Hamstra-Wright, K.L., Bliven, K.C. & Bay, C. (2015). Risk factors for medial tibial stress syndrome in physically active individuals such as runners and military personnel: a systematic review and meta-analysis. *Br J Sports Med*, 49, 362-9.

Hanchard, N.C., Goodchild, L.M., & Kottam, L. (2014). Conservative management following closed reduction of traumatic anterior dislocation of the shoulder. *Cochrane Database Syst Rev*, 4, CD004962.

Harris, J.D., Abrams, G.D., Bach, B.R. et al. (2014). Return to sport after ACL reconstruction. *Orthopedics*, 37, e103-8.

Harris, J.D., Gupta, A.K., Mall, N.A., et al. (2013). Long-term outcomes after Bankart shoulder stabilization. *Arthroscopy*, 29, 920-33.

Hawkins, R.J., Misamore, G.W. & Merritt T.R. (1986). Followup of the acute nonoperated isolated anterior cruciate ligament tear. *Am J Sports Med*, 14, 205-10.

Hawkins, R.J., Morin, W.D., & Bonutti, P.M. (1999). Surgical treatment of full-thickness rotator cuff tears in patients 40 years of age or younger. *J Shoulder Elbow Surg*, 8, 259-65.

Hegedus, E.J., McDonough, S., Bleakley, C., Cook, C.E., & Baxter, G.D. (2015). Clinician-friendly lower extremity physical performance measures in athletes: a systematic review of measurement properties and correlation with injury, part 1. The tests for knee function including the hop tests. *Br J Sports Med*, 49, 642-8.

Helsing A.L. & Bryngelsson, I.L. (2000). Predictors of musculoskeletal pain in men: A twenty-year follow-up from examination at enlistment. *Spine*, 25, 3080-6.

Henning, C.E., Lynch, M.A., & Glick, K.R. (1986). Physical examination of the knee. In J.A. Nicholas & E.B. Hershman (Eds.), *The Lower Extremity and Spine in Sports Medicine* (1667-86). St. Louis: Mosby.

- Hewett, T.E, Di Stasi, S.L. & Myer, G.D. (2013). Current concepts for injury prevention in athletes after anterior cruciate ligament reconstruction. *Am J Sports Med*, 41, 216-24.
- Hirshman, H.P., Daniel, D.M., & Miyasaka, K. (1990). The fate of unoperated knee ligament injuries. In D.M. Daniel, W.H., Akeson, & J.J. O'Connor, eds. *Knee ligaments: structure, function, injury, and repair*, (481-503), New York, NY: Raven Press.
- Hicks, G.S., Duddleston, D.N., Russell, L.D., Holman, H.E., Shepherd, J.M., & Brown, C.A. (2002). Low back pain. *Am J Med Sci*, 324, 207-11.
- Hill, J. & Sachs, M. (1940). The grooved defect of the humeral head. *Radiology*, 35, 690-700.
- Hovellius, L. (1987). Anterior dislocation of the shoulder in teen-agers and young adults. Five-year prognosis. *J Bone Joint Surg Am*, 69, 393-9.
- Hovellius, L., Augustini, B.G., Fredin, H., Johansson, O., Norlin, R., & Thorling, J. (1996). Primary anterior dislocation of the shoulder in young patients. A ten-year prospective study. *J Bone Joint Surg Am*, 78, 1677-84.
- Hovellius, L., Olofsson, A., & Sandstrom, B., et al. (2008). Nonoperative treatment of primary anterior shoulder dislocation in patients forty years of age and younger. a prospective twenty-five-year follow-up. *J Bone Joint Surg Am*, 90, 945-52.
- Hoy, D.G., Protani, M., De, R., & Buchbinder, R. (2010). The epidemiology of neck pain. *Best Pract Res Clin Rheumatol*, 24, 783-92.
- Iannotti, J.P., Bernot, M.P., Kuhlman, J.R., Kelley, M.J., & Williams, G.R. (1996). Postoperative assessment of shoulder function: a prospective study of full-thickness rotator cuff tears. *J Shoulder Elbow Surg*, 5, 449-57.
- Iguchi, T., Kurihara, A., Nakayama, J., Sato, K., Kurosaka, M., & Yamasaki, K. (2000). Minimum 10-year outcome of decompressive laminectomy for degenerative lumbar spinal stenosis. *Spine*, 25, 1754-9.
- Indelicato, P.A., Hermansdorfer, J. & Huegel, M. (1990). Nonoperative management of complete tears of the medial collateral ligament of the knee in intercollegiate football players. *Clin Orthop Relat Res*, 174-7.
- Itoi, E., Hatakeyama, Y., Sato, T., et al. (2007). Immobilization in external rotation after shoulder dislocation reduces the risk of recurrence. A randomized controlled trial. *J Bone Joint Surg Am*, 89, 2124-31.
- Jarvela, T., Kannus, P., Latvala, K., & Jarvinen, M. (2002). Simple measurements in assessing muscle performance after an ACL reconstruction. *Int J Sports Med*, 23, 196-201.
- Jensen, M.C., Brant-Zawadzki, M.N., Obuchowski, N., Modic, M.T., Malkasian, D., & Ross, J.S. (1984). Magnetic resonance imaging of the lumbar spine in people without back pain. *NEJM*, 331, 69-73.
- Jones, R.E., Henley, M.B. & Francis, P. (1986). Nonoperative management of isolated grade III collateral ligament injury in high school football players. *Clin Orthop Relat Res*, 137-40.

- Jones, T.R. & Rao, R.D. (2009). Adult isthmic spondylolisthesis. *J Am Acad Orthop Surg*, 17, 609-17.
- Jonsson, T., Althoff, B., Peterson, L. & Renstrom, P. (1982). Clinical diagnosis of ruptures of the anterior cruciate ligament: a comparative study of the Lachman test and the anterior drawer sign. *Am J Sports Med*, 10, 100-2.
- Juhn, M.S. (1999). Patellofemoral pain syndrome, a review and guidelines for treatment. *Am Fam Physician*, 60, 2012-22.
- Kamper, S.J., Stanton, T.R., Williams, C.M., Maher, C.G. & Hush, J.M. (2011). How is recovery from low back pain measured? A systematic review of the literature. *Eur Spine J*, 20, 9-18.
- Kannus, P. (1988). Long-term results of conservatively treated medial collateral ligament injuries of the knee joint. *Clin Orthop Relat Res*, 103-12.
- Kannus, P. (1989). Nonoperative treatment of grade II and III sprains of the lateral ligament compartment of the knee. *Am J Sports Med*, 17, 83-8.
- Kannus, P., Natri, A., Paakkala, T., & Jarvinen, M. (1999). An outcome study of chronic patellofemoral pain syndrome. Seven-year follow-up of patients in a randomized, controlled trial. *J Bone Joint Surg Am*, 81, 355-63.
- Kasliwal, M.K., Smith, J.S., Kanter, A., et al. (2013). Management of high-grade spondylolisthesis. *Neurosurg Clin N Am*, 24, 275-91.
- Kerkhoffs, G.M., van den Bekerom, M., & Elders, L.A. et al. (2012). Diagnosis, treatment and prevention of ankle sprains, an evidence-based clinical guideline. *Br J Sports Med*, 46, 854-60.
- Kessler, M.A., Behrend, H., Henz, S., Stutz, G., Rukavina, A., & Kuster, M.S. (2008). Function, osteoarthritis and activity after ACL-rupture, 11 years follow-up results of conservative versus reconstructive treatment. *Knee Surg Sports Traumatol Arthrosc*, 16, 442-8.
- Khan, M.N., Jacobs, B.C. & Ashbaugh, S. (2013). Considerations in footwear and orthotics. *Prim Care*, 40, 1001-12.
- Kim, S.G., Nagao, M., Kamata, K., Maeda, K. & Nozawa, M. (2013). Return to sport after arthroscopic meniscectomy on stable knees. *BMC Sports Sci Med Rehabil*, 5, 23.
- Klineberg, E. (2010). Cervical spondylotic myelopathy: a review of the evidence. *Orthop Clin North Am*, 2010;41, 193-202.
- Knapik, J.J., Grier, T., Spiess, A., et al. (2011). Injury rates and injury risk factors among Federal Bureau of Investigation new agent trainees. *BMC Public Health*, 11, 920.
- Kornblum, M.B., Fischgrund, J.S., Herkowitz, H.N., Abraham, D.A., Berkower, D.L., & Ditkoff, J.S. (2004). Degenerative lumbar spondylolisthesis with spinal stenosis: a prospective long-term study comparing fusion and pseudarthrosis. *Spine*, 29, 726-34.
- Kostuik, J.P. (1979). Decision making in adult scoliosis. *Spine*, 4, 521-5.
- Kostuik, J.P. (1980). Recent advances in the treatment of painful adult scoliosis. *Clin Orthop Relat Res*, 238-52.

- Kostuik, J.P. (1990). Operative treatment of idiopathic scoliosis. *J Bone Joint Surg Am*, 72, 1108-13.
- Kostuik, J.P. & Bentivoglio, J. (1981). The incidence of low-back pain in adult scoliosis. *Spine*, 6, 268-73.
- Koumbourlis, A.C. (2006). Scoliosis and the respiratory system. *Paediatr Respir Rev*, 7, 152-60.
- Kreiner, D.S., Hwang, S.W., Easa, J.E., et al. (2014). An evidence based clinical guideline for the diagnosis and treatment of lumbar disc herniation with radiculopathy. *Spine J*, 14, 180-91.
- Krishnan, S.G., Harkins, D.C., Schiffert, S.C., Pennington, S.D., & Burkhead, W.Z. (2008). Arthroscopic repair of full-thickness tears of the rotator cuff in patients younger than 40 years. *Arthroscopy*, 24, 324-8.
- Kyere, K.A., Than, K.D., Wang, A.C., et al. (2012). Schmorl's nodes. *Eur Spine J*, 21, 2115-21.
- Laible, C., Stein, D.A. & Kiridly, D.N. (2013). Meniscal repair. *J Am Acad Orthop Surg*, 21, 204-13.
- LaPrade, R.F. & Wentorf, F. (2002). Diagnosis and treatment of posterolateral knee injuries. *Clin Orthop Relat Res*, 110-21.
- Larsen, K., Weidich, F., & Leboeuf-Yde, C. (2002). Can custom-made biomechanic shoe orthoses prevent problems in the back and lower extremities? A randomized, controlled intervention trial of 146 military conscripts. *J Manipulative Physiol Ther*, 25, 326-31.
- Latimer, J., Maher, C.G., Refshauge, K., & Colaco, I. (1999). The reliability and validity of the Biering-Sorensen test in asymptomatic subjects and subjects reporting current or previous nonspecific low back pain. *Spine*, 24, 2085-90.
- Lee, M.J., Kim, S., Lee, S.A., et al. (2007). Overcoming artifacts from metallic orthopedic implants at high-field-strength MR imaging and multi-detector CT. *Radiographics*, 27, 791-803.
- Lewis, J.S. (2010). Rotator cuff teniopathy, a model for the continuum of pathology and related management. *Br J Sports Med*, 44, 918-23).
- Li, Y. & Hresko, M.T. (2012). Lumbar spine surgery in athletes, outcomes and return-to-play criteria. *Clin Sports Med*, 31, 487-98.
- Lin, E.C., Mall, N.A., Dhawan, A., et al. (2013). Arthroscopic primary rotator cuff repairs in patients aged younger than 45 years. *Arthroscopy*, 29, 811-7.
- Lucantoni, C., Than, K.D., Wang, A.C., et al. (2011). Tarlov cysts: a controversial lesion of the sacral spine. *Neurosurg Focus*, 31, E14.
- Lykissas, M.G., Jain, V.V., Nathan, S.T., et al. (2013). Mid- to long-term outcomes in adolescent idiopathic scoliosis after instrumented posterior spinal fusion: a meta-analysis. *Spine*, 38, E113-9.
- Mall, N.A., Kim, H.M., Keener, J.D., et al. (2010). Symptomatic progression of asymptomatic rotator cuff tears: a prospective study of clinical and sonographic variables. *J Bone Joint Surg Am*, 92, 2623-33.

- Marras, W.S., Ferguson, S.A., Burr, D., Schabo, P., & Maronitis, A. (2007). Low back pain recurrence in occupational environments. *Spine*, 32, 2387-97.
- Matsumoto, M., Fujimura, Y., Suzuki, N., et al. (1998). MRI of cervical intervertebral discs in asymptomatic subjects. *J Bone Joint Surg Br*, 80, 19-24.
- Mattei, T.A. & Rehman, A.A. (2014). Schmorl's nodes: current pathophysiological, diagnostic, and therapeutic paradigms. *Neurosurg Rev*, 37, 39-46.
- McAllister, B.D., Rebholz, B.J., & Wang, J.C. (2012). Is posterior fusion necessary with laminectomy in the cervical spine? *Surg Neurol Int*, 3, S225-31.
- McConnell, J. (1986). The management of chondromalacia patellae: a long term solution. *Aust J Physiother*, 32, 215-23.
- McIntosh, G. & Hall, H. (2011). Low back pain (acute). *BMJ Clin Evid*, (Online).
- Miller, T.T. (2009). MR imaging of the knee. *Sports Med Arthrosc*, 17, 56-67.
- Mink, J.H., Gordon, R.E. & Deutsch, A.L. (2003). The cervical spine: radiologist's perspective. *Phys Med Rehabil Clin N Am*, 14, 493-548, vi.
- Moen, M.H., Holtslag, L., Bakker, E., et al. (2012). The treatment of medial tibial stress syndrome in athletes; a randomized clinical trial. *Sports Med Arthrosc Rehabil Ther Technol*, 4, 12.
- Moen, M.H., Tol, J.L., Weir, A., Steunebrink, M., De Winter, T.C. (2009). Medial tibial stress syndrome: a critical review. *Sports Med*, 39, 523-46.
- Mohankumar, R., White, L.M. & Naraghi, A. (2014). Pitfalls and pearls in MRI of the knee. *Am J Roentgenol*, 203, 516-30.
- Mohtadi, N.G., Webster-Bogaert, S. & Fowler P.J. (1991). Limitation of motion following anterior cruciate ligament reconstruction: A case-control study. *Am J Sports Med*, 19, 620-4; discussion 4-5.
- Molinari, R.W. & Gerlinger, T. (2001). Functional outcomes of instrumented posterior lumbar interbody fusion in active-duty US servicemen: a comparison with nonoperative management. *Spine J*, 1, 215-24.
- Moosmayer, S., Lund, G., Seljom, U.S., et al. (2014). Tendon repair compared with physiotherapy in the treatment of rotator cuff tears: a randomized controlled study in 103 cases with a five-year follow-up. *J Bone Joint Surg Am*, 96, 1504-14.
- Morrissy, R.T., Goldsmith, G.S., Hall, E.C, Kehl, D., & Cowie, G.H. (1990). Measurement of the Cobb angle on radiographs of patients who have scoliosis. Evaluation of intrinsic error. *J Bone Joint Surg Am*, 72, 320-7.
- Nachemson, A., Waddell, G., & Norlund, A. (2000). Epidemiology of neck and low back pain. In A. Nachemson & E. Jonsson (Eds.), *Neck and Back Pain: the Scientific Evidence of Causes, Diagnosis, and Treatment* (p. 495). Philadelphia: Lippincott Williams and Wilkins.
- Nguyen, H.V., Ludwig, S.C., Silber, J., et al. (2004). Rheumatoid arthritis of the cervical spine. *Spine J*, 4, 329-34.

- Nguyen, J.C., De Smet, A.A., Graf, B.K., & Rosas, H.G. (2014). MR imaging-based diagnosis and classification of meniscal tears. *Radiographics*, 34, 981-99.
- Nguyen, T.H. & Randolph, D.C. (2007). Nonspecific low back pain and return to work. *Am Fam Physician*, 76, 1497-502.
- Nimon, G., Murray, D., Sandow, M. & Goodfellow, J. (1998). Natural history of anterior knee pain: a 14- to 20-year follow-up of nonoperative management. *J Pediatr Orthop*, 18, 118-22.
- Nordgren, B., Schele, R., & Linroth, K. (1980). Evaluation and prediction of back pain during military field service. *Scand J Rehabil Med*, 12(1), 1-8.
- North, R.B. & Linderoth, B., eds. (2010). *Spinal Cord Stimulation*. 4th ed. Baltimore, MD: Lippincott Williams & Wilkins.
- Noyes, F.R., Cummings, J.F., Grood, E.S., Walz-Hasselfeld, K.A., Wroble, R.R. (1991). The diagnosis of knee motion limits, subluxations, and ligament injury. *Am J Sports Med*, 19, 163-71.
- Noyes, F.R., Mooar, L.A., Moorman, C.T., 3rd, McGinniss, G.H. (1989). Partial tears of the anterior cruciate ligament. Progression to complete ligament deficiency. *J Bone Joint Surg Br*, 71, 825-33.
- Nyland, J., Brosky, T., Currier, D., Nitz, A., & Caborn, D. (1994). Review of the afferent neural system of the knee and its contribution to motor learning. *J Orthop Sports Phys Ther*, 19, 2-11.
- Nyland, J., Caborn, D.N., Johnson, D.L., Moore, J., & Slone, K. (1998). Patellar tendon ACL reconstruction and rehabilitation practices and opinions (autograft versus allograft), orthopaedic sports medicine fellowship program survey. *J South Orthop Assoc*, 7, 13-8.
- Olds, M., Ellis, R., Donaldson, K., Parmar, P., & Kersten, P. (2015). Risk factors which predispose first-time traumatic anterior shoulder dislocations to recurrent instability in adults: a systematic review and meta-analysis. *Br J Sports Med*, 49, 913-22.
- Onks, C.A. & Billy, G. (2013). Evaluation and treatment of cervical radiculopathy. *Prim Care*, 40, 837-48, vii-viii.
- Page, M.J., Massy-Westropp, N., O'Connor, D., & Pitt, V. (2012). Splinting for carpal tunnel syndrome. *Cochrane Database Syst Rev*, 7, CD010003.
- Page, M.J., O'Connor, D., Pitt, V., & Massy-Westropp, N. (2012). Exercise and mobilisation interventions for carpal tunnel syndrome. *Cochrane Database Syst Rev*, 6, CD009899.
- Paterson, W.H., Throckmorton, T.W., Koester, M., Azar, F.M., & Kuhn, J.E. (2010). Position and duration of immobilization after primary anterior shoulder dislocation: a systematic review and meta-analysis of the literature. *J Bone Joint Surg Am*, 92, 2924-33.
- Pathria, M.N. (2008). A Radiologic Perspective: Imaging of the Spine in Sports Medicine. In R.A. Pedowitz, C.B. Chung, & D. Resnick (Eds.), *Magnetic Resonance Imaging in Orthopaedic Sports Medicine* (pp. 113-34). New York: Springer.
- Pedowitz, R.A., Yamaguchi, K., Ahmad, C.S., et al. (2011). Optimizing the management of rotator cuff problems. *J Am Acad Orthop Surg*, 19, 368-79.

Porcellini, G., Campi, F., Pegreff, F., Castagna, A., & Paladini, P. (2009). Predisposing factors for recurrent shoulder dislocation after arthroscopic treatment. *J Bone Joint Surg Am*, 91, 2537-42.

Pugh, L., Mascarenhas, R., Arneja, S., Chin, P.Y., & Leith, J.M. (2009). Current concepts in instrumented knee-laxity testing. *Am J Sports Med*, 37, 199-210.

Pujol, N., Colombet, P., Cucurulo, T., et al. (2012). Natural history of partial anterior cruciate ligament tears: a systematic literature review. *Orthop Traumatol Surg Res*, 98, S160-4.

Rainville, J. (2004). Nondegenerative spondylolisthesis: epidemiology and natural history, classification, history and physical examination, and nonoperative treatment of adults. In H. Herkowitz, J. Dvorak, G. Bell, M. Nordin, & D. Grob, D. (Eds.), *The Lumbar Spine* (p. 943). Philadelphia: Lippincott Williams and Wilkins.

Ramsey, M.L., Getz, C.L., & Parsons, B.O. (2010). What's new in shoulder and elbow surgery. *J Bone Joint Surg Am*, 92, 1047-61.

Ramski, D.E., Kanj, W.W., Franklin, C.C., Baldwin, K.D., & Ganley, T.J. (2014). Anterior cruciate ligament tears in children and adolescents: a meta-analysis of nonoperative versus operative treatment. *Am J Sports Med*, 42, 2769-76.

Remes, V., Helenius, I., Schlenzka, D., Yrjonen, T., Ylikoski, M., & Poussa, M. (2004). Cotrel-Dubousset (CD) or Universal Spine System (USS) instrumentation in adolescent idiopathic scoliosis (AIS): comparison of midterm clinical, functional, and radiologic outcomes. *Spine*, 29, 2024-30.

Reshef, N. & Guelich, D.R. (2012). Medial tibial stress syndrome. *Clin Sports Med*, 31, 273-90.

Rhee, Y.G., Cho, N.S., & Cho, S.H. (2009). Traumatic anterior dislocation of the shoulder: factors affecting the progress of the traumatic anterior dislocation. *Clin Orthop Surg*, 1, 188-93.

Rice, S.G. (2008). American Academy of Pediatrics Council on Sports Medicine and Fitness. Medical conditions affecting sports participation. *Pediatrics*, 121(4), 841-8.

Rihn, J.A., Harrod, C., & Albert, T.J. (2012). Revision cervical spine surgery. *Orthop Clin North Am*, 43, 123-36, ix-x.

Rishiraj, N., Taunton, J.E., Lloyd-Smith, R., Woollard, R., Regan, W., & Clement, D.B. (2009). The potential role of prophylactic/functional knee bracing in preventing knee ligament injury. *Sports Med*, 39, 937-60.

Roberts, H.C., Denison, H.J., Martin, H.J., et al. (2011). A review of the measurement of grip strength in clinical and epidemiological studies: towards a standardised approach. *Age Ageing*, 40, 423-9.

Rohman, E., Steubs, J.T. & Tompkins, M. (2015). Changes in involved and uninvolved limb function during rehabilitation after anterior cruciate ligament reconstruction: implications for limb symmetry index measures. *Am J Sports Med*, 43, 1391-8.

Rubery, P.T. & Bradford, D.S. (2002). Athletic activity after spine surgery in children and adolescents: results of a survey. *Spine*, 27, 423-7.

- Ryan, J. & Zwerling, C. (1990a). Risk for occupational low-back injury after lumbar laminectomy for degenerative disc disease. *Spine*, 15, 500-3.
- Ryan, J. & Zwerling, C. (1990b). Severity of disability due to occupational low back injury after lumbar laminectomy for degenerative disc disease. *J Occup Med*, 32, 468-72.
- Sahin, G. & Demirtas, M. (2006). An overview of MR arthrography with emphasis on the current technique and applicational hints and tips. *Eur J Radiol*, 58, 416-30.
- Sanati, K.A., Mansouri, M., Macdonald, D., Ghafghazi, S., Macdonald, E., & Yadegarfar, G. (2011). Surgical techniques and return to work following carpal tunnel release: a systematic review and meta-analysis. *J Occup Rehabil*, 21, 474-81.
- Sanders, J.O., Browne, R.H., McConnell, S.J., Margraf, S.A., Cooney, T.E., & Finegold, D.N. (2007). Maturity assessment and curve progression in girls with idiopathic scoliosis. *J Bone Joint Surg Am*, 89, 64-73.
- Sansone, V. & De Ponti, A. (1999). Arthroscopic treatment of popliteal cyst and associated intra-articular knee disorders in adults. *Arthroscopy*, 15, 368-72.
- Sardar, Z.M., Ouellet, J.A., Fischer, D.J., & Skelly, A.C. (2013). Outcomes in adult scoliosis patients who undergo spinal fusion stopping at L5 compared with extension to the sacrum. *Evid Based Spine Care J*, 4, 96-104.
- Schneider, G.A., Bigelow, C. & Amoroso, P.J. (2000). Evaluating risk of re-injury among 1214 army airborne soldiers using a stratified survival model. *Am J Prev Med*, 18, 156-63.
- Schroeder, G.D., McCarthy, K.J., Micev, A.J., Terry, M.A., & Hsu, W.K. (2013). Performance-based outcomes after nonoperative treatment, discectomy, and/or fusion for a lumbar disc herniation in National Hockey League athletes. *Am J Sports Med*, 41, 2604-
- Schwab, F., Lafage, V., Farcy, J.P., et al. (2007). Surgical rates and operative outcome analysis in thoracolumbar and lumbar major adult scoliosis: application of the new adult deformity classification. *Spine*, 32, 2723-30.
- Shelbourne, K.D., Patel, D.V., Adsit, W.S., & Porter, D.A. (1996). Rehabilitation after meniscal repair. *Clin Sports Med*, 15, 595-612.
- Shen, F.H., Samartzis, D., Jenis, L.G. & An, H.S. (2004). Rheumatoid arthritis: evaluation and surgical management of the cervical spine. *Spine J*, 4, 689-700.
- Sierink, J.C., van Lieshout, W.A., Beenen, L.F, Schep, N.W., Vandertop, W.P., & Goslings, J.C. (2013). Systematic review of flexion/extension radiography of the cervical spine in trauma patients. *Eur J Radiol*, 82, 974-81.
- Simonet, W.T. & Cofield, R.H. (1984). Prognosis in anterior shoulder dislocation. *Am J Sports Med*, 12, 19-24.
- Smith, M.A. & Smith, W.T. (2010). Rotator cuff tears: an overview. *Orthop Nurs*, 29, 319-22; quiz 23-24.

- Souza, R.B., Draper, C.E., Fredericson, M., Powers, C.M. (2010). Femur rotation and patellofemoral joint kinematics: a weight-bearing magnetic resonance imaging analysis. *J Orthop Sports Phys Ther*, 40, 277-85.
- Stanton, T.R., Latimer, J., Maher, C.G., & Hancock, M.J. (2011). A modified Delphi approach to standardize low back pain recurrence terminology. *Eur Spine J*, 20, 744-52.
- Stathopulu, E. & Baildam, E. (2003). Anterior knee pain: a long-term follow-up. *Rheumatology (Oxford)*, 42, 380-2.
- Stefancin, J.J. & Parker, R.D. (2007). First-time traumatic patellar dislocation, a systematic review. *Clin Orthop Relat Res*, 455, 93-101.
- Stiell, I.G., Greenberg, G.H., McKnight, R.D., Nair, R.C., McDowell, I., & Worthington, J.R. (1992). A study to develop clinical decision rules for the use of radiography in acute ankle injuries. *Ann Emerg Med*, 21, 384-90.
- Strauss, E.J., Kim, S., Calcei, J.G., & Park, D. (2011). Iliotibial band syndrome, evaluation and management. *J Am Acad Orthop Surg*, 19, 728-36.
- Sullivan, C.S. & Shimizu, K.T. (1988). Epidemiological studies of work-related injuries among law enforcement personnel. *J Soc Occup Med*, 38, 33-40.
- Sullivan, L.G., Bailie, R., Weiss, N., & Miller, B.S. (2007). An evaluation of shoulder external rotation braces. *Arthroscopy*, 23, 129-34.
- Taft, T.N., Wilson, F.C., & Oglesby, J.W. (1987). Dislocation of the acromioclavicular joint. An end-result study. *J Bone Joint Surg Am*, 69, 1045-51.
- Tanaka, Y., Okamura, K., & Imai, T. (2010). Effectiveness of external rotation immobilization in highly active young men with traumatic primary anterior shoulder dislocation or subluxation. *Orthopedics*, 33, 670.
- Taunton, J.E., Ryan, M.M., Clement, D.B., McKenzie, D.C, Lloyd-Smith, D.R., Zumbo, B.D. (2002). A retrospective case-control analysis of 2002 running injuries. *Br J Sports Med*, 36, 95-101.
- Tegner, Y. & Lysholm J. (1985). Derotation brace and knee function in patients with anterior cruciate ligament tears. *Arthroscopy*, 1, 264-7.
- Thangarajah, T. & Lambert, S. (2015). Management of the unstable shoulder. *BMJ*, 350, h2537.
- Torg, J.S. (1995). Cervical spinal stenosis with cord neurapraxia and transient quadriplegia. *Sports Med*, 20, 429-34.
- Torg, J.S., Corcoran, T.A., Thibault, L.E., et al. (1997). Cervical cord neurapraxia: classification, pathomechanics, morbidity, and management guidelines. *J Neurosurg*, 87, 843-50.
- Torg, J.S., Naranja, R.J., Jr., Pavlov, H., Galinat, B.J., Warren, R., & Stine, R.A. (1996). The relationship of developmental narrowing of the cervical spinal canal to reversible and irreversible injury of the cervical spinal cord in football players. *J Bone Joint Surg Am*, 78, 1308-14.

- Undheim, M.B., Cosgrave, C., King, E., et al. (2015). Isokinetic muscle strength and readiness to return to sport following anterior cruciate ligament reconstruction: is there an association? A systematic review and a protocol recommendation. *Br J Sports Med*.
- Vaccaro, A., Klein, G., Ciccoti, M., et al. (2002). Return to play criteria for the athlete with cervical spine injuries resulting in stinger and transient quadriplegia/paresis. *The Spine Journal*, 2, 351-6.
- van der Windt, D.A., Simons, E., Riphagen, I.I., et al. (2010). Physical examination for lumbar radiculopathy due to disc herniation in patients with low-back pain. *Cochrane Database Syst Rev*, 10, CD007431.
- Van Dyck, P., Gielen, J., D'Anvers, J., et al. (2007). MR diagnosis of meniscal tears of the knee: analysis of error patterns. *Arch Orthop Trauma Surg*, 127, 849-54.
- van Tulder, M., Assendelft, W.J., Koes, B.W., & Bouter, L.M. (1997). Spinal radiographic findings and nonspecific low back pain. A systematic review of observational studies. *Spine*, 22, 427-34.
- van Tulder, M., Becker, A., Bekkering, T., et al. (2006). Chapter 3. European guidelines for the management of acute nonspecific low back pain in primary care. *Eur Spine J*, 15(S2), S169-91.
- Vavken, P., Sadoghi, P., Quidde, J., et al. (2014). Immobilization in internal or external rotation does not change recurrence rates after traumatic anterior shoulder dislocation. *J Shoulder Elbow Surg*, 23, 13-9.
- Veth, R. (1985). Clinical significance of knee joint changes after meniscectomy. *Clin Orthop Relat Res*, 198, 56-60.
- Vibert, B.T., Sliva, C.D., & Herkowitz, H.N. (2006). Treatment of instability and spondylolisthesis: surgical versus nonsurgical treatment. *Clin Orthop Relat Res*, 443, 222-7.
- Waddell, G. & Burton, A.K. (2001). Occupational health guidelines for the management of low back pain at work: evidence review. *Occup Med (Lond)*, 51, 124-35.
- Wang, D., Jones, M.H., Khair, M.M. & Miniaci, A. (2010). Patient-reported outcome measures for the knee. *J Knee Surg*, 23, 137-51.
- Wang, Y., Videman, T., & Battie, M.C. (2012). ISSLS prize winner, Lumbar vertebral endplate lesions: associations with disc degeneration and back pain history. *Spine*, 37, 1490-6.
- Warren, R.F. (1983). Subluxation of the shoulder in athletes. *Clin Sports Med*, 2, 339-54.
- Watkins, R.G. & Dillin, W.H. (1990). Lumbar spine injury in the athlete. *Clin Sports Med*, 9, 419-48.
- Watkins, R.G.T., Hanna, R., Chang, D., & Watkins, R.G., 3rd. (2012). Return-to-play outcomes after microscopic lumbar discectomy in professional athletes. *Am J Sports Med*, 40, 2530-5.
- Weber, H. (1990). Natural history of the herniated disc. In J.N.Weinstein & S. Wiesel (Eds.), *The Lumbar Spine* (pp. 381-2). Philadelphia: W.B Saunders.

- Weinstein, J.N., Tosteson, T.D., Lurie, J.D., et al. (2010). Surgical versus nonoperative treatment for lumbar spinal stenosis four-year results of the Spine Patient Outcomes Research Trial. *Spine*, 35, 1329-38.
- Weinstein, J.N., Lurie, J.D., Tosteson, T.D., et al. (2008). Surgical versus nonoperative treatment for lumbar disc herniation: four-year results for the Spine Patient Outcomes Research Trial (SPORT). *Spine*, 33, 2789-800.
- Weinstein, S.L., Dolan, L.A., Cheng, J.C, Danielsson, A., & Morcuende, J.A. (2008). Adolescent idiopathic scoliosis. *Lancet*, 371, 1527-37.
- Weinstein, J.N., Lurie, J.D., Tosteson, T.D., et al. (2009). Surgical compared with nonoperative treatment for lumbar degenerative spondylolisthesis. four-year results in the Spine Patient Outcomes Research Trial (SPORT) randomized and observational cohorts. *J Bone Joint Surg Am*, 91, 1295-304.
- Weinstein, S.L. & Ponseti, I.V. (1983). Curve progression in idiopathic scoliosis. *J Bone Joint Surg Am*, 65, 447-55.
- Weinstein, S.L., Dolan, L.A., Spratt, K.F., Peterson, K.K., Spoonamore, M.J., & Ponseti, I.V. (2003). Health and function of patients with untreated idiopathic scoliosis: a 50-year natural history study. *JAMA*, 289, 559-67.
- White, B.J. & Sherman, O.H. (2009). Patellofemoral instability. *Bull NYU Hosp Jt Dis*, 67, 22-9.
- White, A.A., 3rd, Johnson, R.M., Panjabi, M.M., & Southwick, W.O. (1975). Biomechanical analysis of clinical stability in the cervical spine. *Clin Orthop Relat Res*, 85-96.
- Wiesel, S. (1989). Compensation neck pain. In Society ECCSR, ed. *The Cervical Spine* (pp. 823-30). Philadelphia: Lippincott Williams and Wilkins.
- Wills, A.K, Ramasamy, A., Ewins, D.J. & Etherington, J. (2004). The incidence and occupational outcome of overuse anterior knee pain during army recruit training. *J R Army Med Corps*, 150, 264-9.
- Winters, M., Eskes, M., Weir, A., Moen, M.H., Backx, F.J., & Bakker, E.W. (2013). Treatment of medial tibial stress syndrome: a systematic review. *Sports Med*, 43, 1315-33.
- Wong, H.K. & Tan, K.J. (2010). The natural history of adolescent idiopathic scoliosis. *Indian J Orthop*, 44, 9-13.
- Yamamoto, N., Sano, H., & Itoi, E. (2010). Conservative treatment of first-time shoulder dislocation with the arm in external rotation. *J Shoulder Elbow Surg*, 19, 98-103.
- Youssef, J.A., Orndorff, D.O, Patty, C.A., et al. (2013). Current Status of Adult Spinal Deformity. *Global Spine J*, 3, 51-62.
- Zigler, J., Delamarter, R., Spivak, J.M., et al. (2007). Results of the prospective, randomized, multicenter Food and Drug Administration investigational device exemption study of the ProDisc-L total disc replacement versus circumferential fusion for the treatment of 1-level degenerative disc disease. *Spine*, 32, 1155-1163.